

Ectopic dental inclusion: A literature review

Paulina Chimborazo Buestan ^{1,*}, Jherel Maldonado Cruz ¹ and Paul Guillen Guerrero ²

¹ Dentistry School, University of Cuenca, Cuenca, Ecuador.

² Surgery's Department, Dentistry School, University of Cuenca, Cuenca, Ecuador.

World Journal of Advanced Research and Reviews, 2022, 16(01), 218–227

Publication history: Received on 03 September 2022, revised on 04 October 2022, accepted on 07 October 2022

Article DOI: <https://doi.org/10.30574/wjarr.2022.16.1.1012>

Abstract

Objective: Analyze the publications on ectopic dental inclusion, as well as its risk factors, prevalence and respective treatments.

Materials and methods: A literature review was carried out including articles from the year 2000 to 2021 in the databases: Medline/PubMed, SciELO and Google Scholar. Thirty-seven bibliographic references of interest were used for the study, of which 18 case report and case series articles were selected for the analysis of clinical, pathological, and radiographic information, as well as patient demographics, anatomical location of ectopic teeth, clinical symptomatology, and treatment modalities.

Results: It was determined that the dental group with the highest incidence is the third molar with 68%, followed by canines with 12%, while the remaining 20% is comprised of: second molar, second premolar, supernumerary and unspecified tooth. The prevalence in relation to gender refers to 68% in women and the most common age range of its diagnosis is the third decade of life in 40%. Regarding associated lesions, 40% correspond to dentigerous cyst, 16% to granuloma, 28% without associated lesion, 4% radicular cyst and the remaining 12% do not mention lesion. The treatment for a patient with ectopic dental inclusion varies depending on its presentation characteristics, but it is usually resolved through a surgical approach and periodic radiographic clinical controls.

Conclusion: Ectopic dental inclusion has a prevalence of appearance in the third decade of life, usually when patients present symptoms and before routine radiographic examination, the most satisfactory treatment is the intraoral approach, finally the prognosis in these patients is satisfactory.

Keywords: Included tooth, Risk factors, Prevalence, Maxilla, Mandible

1. Introduction

Dental eruption is a process in which the tooth, through its axial displacement, passes from a non-functional position in the bone to a physiological occlusion in the oral cavity (1). From an embryological point of view, every process is born from the interaction between the epithelium and the mesenchyme, coming from the neural crest. During the third month of fetal development, the dental follicles of the permanent pieces are formed, these will be located on the lingual face of the temporary pieces, until the sixth year of life when the replacement will begin, causing the displacement of the temporary teeth outside the arch (2).

At the end of the eruption process, when the tooth is in its correct position, it will fulfill its masticatory, aesthetic and phonetic function. Sometimes the tooth suffers a deviation from the eruption path causing it not to emerge correctly,

* Corresponding author: Paulina Chimborazo Buestan
Dentistry School, University of Cuenca, Cuenca, Ecuador.

for which it is usually found enclosed within the bone associated with two important parameters: impaction and retention. In the case of impaction, a mechanical obstacle that prevents normal eruption is identified, while in dental retention this physical barrier does not exist (3). In short, dental inclusion is caused when the tooth remains within the bone, encompassing the concepts of primary retention and bone impaction (3).

In cases of ectopic dental inclusion, alterations of both the final position of the tooth and the direction of eruption are involved, therefore they are classified as: transposition, when the tooth occupies a place adjacent to its corresponding position, transmigration, when the tooth crosses the midline to the opposite side to which it belongs (4). In this way, ectopic dental inclusion is generally determined when the tooth moves to an unusual place and distance from its regular site, affecting either a temporary, permanent or supernumerary tooth that is located in a non-dental region, such as the sinus. maxilla, nasal cavity, orbit, mandibular condyle, coronoid process and palate (2,5). The objective of this literature review is to analyze the publications on ectopic dental inclusion, as well as its risk factors, prevalence and respective treatments.

2. Material and methods

For this study, a systematic literature review was carried out with scientific information about the research topic. This search included articles from the year 2000 to 2021 in the following databases: Medical Literature Analysis and Retrieval System Online (Medline/PubMed), Scientific Electronic Library Online (SciELO) and Scholar Google.

Additionally, key terms available in Medical Subject Headings (MeSH) were used together with Boolean operators: and, or, not, thus, determining the following keywords: included tooth, risk factors, prevalence, maxilla and mandible.

The inclusion criteria specified for this article were: meta-analysis, systematic reviews, case reports, literature reviews that described, reported and reviewed ectopic dental inclusions, meanwhile, the exclusion criteria were reports of iatrogenic displacement of the third molar.

Finally, 37 bibliographic references of interest were included, of which 18 case report and case series articles were selected exclusively for the analysis of clinical, pathological, and radiographic information, as well as patient demographics, anatomical location of ectopic teeth, and treatment modalities. The data obtained in the selected articles were included in a database, Excel (Microsoft Office Professional 2019 for Windows) was used and tables were made to facilitate their interpretation.

3. State of art

3.1. Risk factors

The etiology of ectopic dental inclusion remains unknown, however, the current scientific literature associates this clinical entity with multiple factors, including a genetic component and other local factors (1), and is even associated with various biological factors. Genetic factors affect the tissues and cells involved in the eruption of multiple teeth, for example, in patients with certain developmental syndromes (6). On the other hand, local factors come mainly from physical barriers that obstruct normal eruption and affect only a few permanent teeth (6). Eruption alterations due to local factors are common in the canine or molar area and can be caused by: the presence of post-surgical fibromatous scar tissue, inflammation, premature loss of primary teeth and lack of space within the dental arch (6). Other suggested causes include developmental abnormalities such as: cleft palate, trauma, rhinogenic or odontogenic infections, genetic factors, and crowding or other associated pathologies surrounding the impacted tooth. On the other hand, the factors that favor the formation of ectopic teeth may be factors of embryological or genetic origin, among others, such as the underdeveloped maxilla and mouth breathers, because this type of breathing causes a narrow maxilla (7). In addition, systemic factors such as osteoporosis or metabolic disorders such as rickets or Down syndrome, contributes to poor dentition or ectopic dental position (7).

Previous studies have reported that poor maxillary growth, a large first permanent molar, cleft lip and palate, supernumerary teeth, in addition to weight and height deficiency, are associated with the appearance of ectopic dental inclusion (8). Other authors describe that the etiology of an ectopic tooth is still controversial, because many theories associate developmental and displacement defects with conditions such as: trauma, tumors or cysts. Any abnormal tissue interaction during the odontogenesis process can result in the development of this pathology (2).

On the other hand, some professionals focus on the etiology of a dental group such as ectopic molar eruption, associated in the same way to a pathological disorder of multifactorial etiology, although the causes are not fully elucidated (9). The prevalence varies from 0.75 to 11.8%, with a range of up to four times higher in patients with cleft lip and palate. A genetic or hereditary component can be considered due to a higher prevalence described among brothers (19.8%), and a recessive inheritance pattern has even been suggested in girls. While some authors cite a higher incidence in boys, others do not find statistically significant differences between the genres (10).

3.2. Epidemiology

The term ectopic tooth refers to a clinical entity characterized by the presence of a tooth located in a non-dental area, distant from its usual anatomical location. The frequency is relatively rare, consequently, it is difficult to specify percentages because there are no studies that refer to the presence of these ectopics, they generally remain asymptomatic for several years before being diagnosed, therefore it is normal that they go unnoticed or they are simply not reported in the literature (11). The dental group with the highest frequency of ectopic inclusion are: third molars and canines (12).

The reported cases are unusual and each of these present individual peculiarities. In the case of maxillary teeth, its most frequent ectopic location is in the maxillary sinus (13-15), in some cases it can also be located at the infraorbital level and on the orbital rim (16,17), meanwhile, the location in the subcondylar or condylar region becomes the most common site of lower ectopic teeth (18). To conclude, in relation to race it has been shown that the frequency of ectopic dental inclusions in black people is minimal, it is speculated that this is due to the greater volume of their jaws (18).

3.3. Treatment

Radiological examination can easily detect and diagnose ectopic teeth, due to their radiopaque image in unusual bony structures of the facial mass. Computerized axial tomography is the gold standard to determine the definitive anatomical location as well as its commitments with regional anatomical structures (13). Ectopic dental inclusion is a rare entity, for this reason its surgical management is not subject of consensus. Certain articles have been published in the literature, most of these clinical cases. The therapeutic choice for ectopic dental inclusion is based on: clinical presentation, radiographic images, surgical risks, complications and the patient's choice.

Surgical intervention is indicated when the tooth causes discomfort, clinical symptoms or is associated with a pathological lesion, such as a dentigerous cyst. Surgery in the case of radiographic findings, in which the patient is asymptomatic, will depend on the risk of: fracture or bone deformation, functional problems, infection and the patient's predisposition. In the case that the option of not intervening surgically is chosen, either due to a high age that puts the life of the patient at risk or the absence of symptoms without evidence of cystic lesion, regular follow-up is required through clinical check-ups every 6-8 months (7,18,19,20). In a systematic review conducted by Veerabhadrapa et al. (11) concluded that asymptomatic cases of ectopic mandibular dental inclusions require annual follow-up visits with orthopantomography to monitor migration or the appearance of any lesion. However, it will be the surgeon who, according to the clinical characteristics, determines if additional radiological examinations are necessary (11).

In the case of ectopic teeth in the maxillary sinus or the nostrils floor, the intraoral surgical approach will be the first choice, while in dentigerous cysts associated with an ectopic tooth in the maxillary sinus, surgical management will depend on the extent and invasion of the cyst to the surrounding structures, the aesthetic and functional importance of the included tooth, the size of the cyst and the age of the patient. The therapeutic option may be enucleation or marsupialization accompanied by the extraction of the tooth. The best surgical approach choice in these cases is the Caldwell-Luc technique, however, the literature has reported advantages of the quadrangular approach, which reduces the bone defect, obtaining direct visibility of the internal walls of the maxillary sinus (15, 16, 21, 34).

An intraoral approach is often recommended to avoid visible scarring, however, in specific situations, this type of approach is not ideal, due to the limited surgical field and poor visualization in inaccessible anatomical regions. These disadvantages, as well as the lack of scientific evidence on the best surgical approach, cause doubts about optimal management treatment of ectopic dental inclusions (20,22).

Additionally, in a study called "An evaluation of surgical practices at the National Congress of the French Society of Stomatology, Maxillofacial and Oral Surgery, and meta-analysis of ectopic third molars located in the lower jaw", it was concluded that the surgical approach of preference was the intraoral, except when the ectopically included teeth are located in the condyle, or a skin fistula was present, which in turn was preferred to simultaneously perform osteosynthesis or a graft (19,20).

Furthermore, in the case that the ectopic tooth is in the condyle and an extraoral surgical approach is decided, a preauricular approach can be chosen, with the aim of reducing surgical morbidity and risk of iatrogenic injury, however, Ruiz et al. (24), propose a better extraoral therapeutic option called modified endoaural approach, which consists of obtaining an approach with high aesthetic parameters, and a wide field of visibility that generates minimal complications (23, 24).

4. Results

Thirty-seven bibliographic references of interest were used for the study, of which 18 case report and case series articles describe 25 ectopic dental inclusions. They were selected exclusively for the analysis of clinical, pathological, and radiographic information, as well as the demographics of the patients, anatomical location of the ectopic teeth and treatment modalities, all these data are summarized in Table 1.

Table 1 Literature review, ectopic dental inclusions

N°	Searcher	Author	Year	Dental piece	Location	Symptoms	Treatment	Associated injury
1	PubMed	Buyukkur t (25)	2010	-Third molar - Canine - Third molar	Maxillary sinus	- Swelling - Swelling, pain. - Swelling	Intraoral surgical extraction, Caldwell-Luc approach	a, b and c Dentigerous cyst.
2	PubMed	Ray (14)	2009	Supernumerary	Maxillary sinus	Intermittent mucooid discharge from the inner eye corner	Intraoral surgical extraction, Caldwell-Luc approach	Dentigerous cyst.
3	PubMed	Okuyama (26)	2016	Third molar	Subcondylar region	Lockjaw, repeated episodes of swelling and pain in the preauricular area	Intraoral surgical extraction	Inflammatory granulation tissue.
4	PubMed	Hanisch (27)	2016	Third molar	Sigmoid notch	Pain and swelling in the preauricular region or trismus	Intraoral surgical extraction	Granulation tissue with chronic inflammation.
5	PubMed	Findik (28)	2015	Third molar	Sigmoid notch	Asymptomatic	Intraoral surgical extraction	Dentigerous cyst.
6	PubMed	Buchanan (29)	2008	Third molar	Maxillary sinus	Frontal mucocele and maxillary sinusitis	Intraoral surgical extraction, Caldwell-Luc approach	Does not mention.
7	PubMed	Ramanojam (30)	2013	-Second premolar - Third molar - Third molar - Not specific - Canine - Third molar	-Maxillary sinus -Maxillary sinus -Maxillary sinus -Maxillary tuberosity. -Maxillary sinus -Maxillary sinus	-Pain and swelling in the region of the right cheek, cystic lesion -Heaviness, hypoesthesia on the cheek.	- Enucleation - Caldwell-Luc approach -Surgical removal, Caldwell-Luc approach - Tracing	a, b and c dentigerous cyst d and e. No injury. F. Does not mention.

						-Occasional dull TMJ pain -Asymptomatic - Dull pain - Dull pain in cheek	e. Tracing f. Enucleation - Caldwell-Luc approach	
8	PubMed	Kim (31)	2011	Third molar	Mandibular condyle	Discomfort in the left preauricular area during chewing and mouth opening.	Tracing	No injury.
9	SciELO	Sanchis (32)	2016	Third molar	Subcondylar region	Discomfort and nonspecific hemifacial pain with episodes of swelling	Intraoral surgical extraction	Chronically inflamed granulation tissue
10	SciELO	Antunes (15)	2011	Third molar	Maxillary sinus	Asymptomatic	Intraoral surgical extraction. Caldwell–Luc approach	Dentigerous cyst.
11	SciELO	Moreno (16)	2007	Third molar	Infraorbital	Sensation of right hemifacial tension and pain on palpation.	Intraoral surgical extraction, Caldwell-Luc approach.	Radicular cyst.
12	SciELO	Delys (21)	2013	Third molar	Condyle	Sensation of hemifacial tension, pain on palpation, episodes of inflammation, slight facial asymmetry	Extraoral surgical extraction and exeresis	Dentigerous cyst.
13	Scholar Google	Albarracin (33)	2020	Third molar	Communication with nasal cavity floor	Sporadic nosebleeds	Intraoral surgical extraction, circumvestibular approach	Does not mention.
14	Scholar Google	Cazar (34)	2017	Third molar	Maxillary sinus	Asymptomatic	Intraoral surgical extraction, circumvestibular approach	No injury.
15	Scholar Google	Fernandez (35)	2014	Unspecified molar	Maxillary sinus	Recurrent purulent rhinorrhea, unilateral nasal obstruction and paranasal pain, in addition to diffuse referred	Intraoral surgical extraction, circumvestibular approach	No injury.

						pain and halitosis.		
16	Scholar Google	Duran (36)	2021	Second molar	Maxillary sinus	Pneumonia	Intraoral surgical extraction	Granulation tissue with chronic inflammation
17	Scholar Google	Maura (37)	2019	Central incisor	Lateral wall of nasal cavity	Complaint of foreign body in the nose	Intraoral surgical extraction, circumvestibular approach	No injury.
18	Scholar Google	Campos (17)	2019	Third molar	Orbital rim	Slight enlargement of the orbital rim	Intraoral surgical extraction, circumvestibular approach	No injury.

4.1. Affected tooth group

The 25 reported cases reveal that the dental group with the highest prevalence of ectopic inclusion are the third molars, present in 17 cases representing 68%, followed by canines representing 12%, second molars 8%. Contrary to these results, the lowest prevalence of ectopic dental pieces is found in the second premolar 4%, central incisor 4% and supernumerary 4%, since only one case is presented respectively (Table 1).

4.2. Radiographic features (anatomical location)

The anatomical position in which these dental pieces are frequently located, summarized in (Table 1) and represented in (Figure 1), show that the anatomical region of the upper ectopic dental inclusions is the maxillary sinus, followed by the nasal cavity and infraorbital rim. On the other hand, the areas of the lower jaw where ectopic teeth occur are the condylar region, subcondylar region and the sigmoid notch.

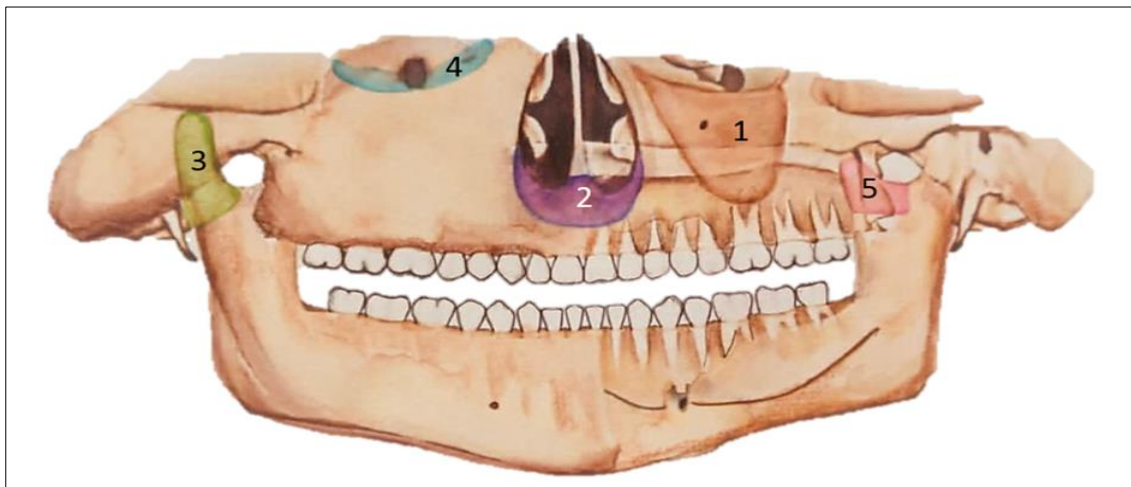

Figure 1 Prevalence of anatomical zones in which ectopic dental pieces are located: 1, maxillary sinus, 2, nasal cavity, 3, mandibular condyle, 4, infraorbital rim, 5, sigmoid notch

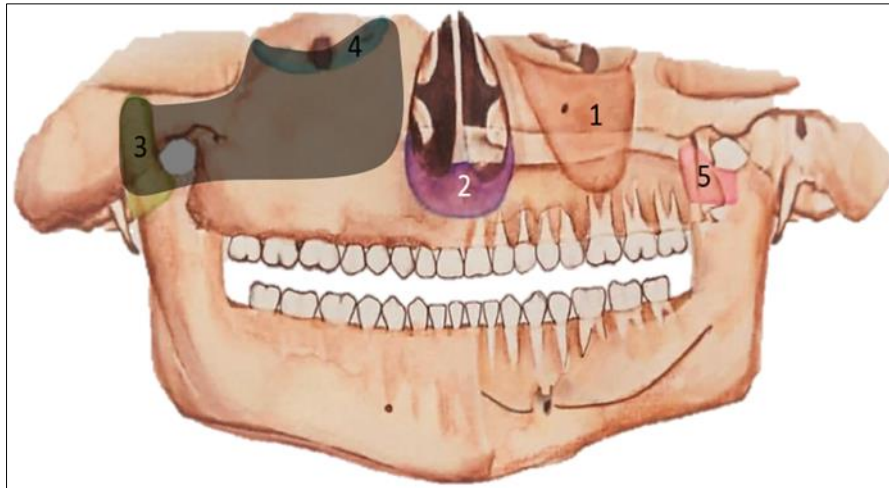


Figure 2 Most frequent areas (black color) of location of ectopic tooth (Third molar) with higher prevalence in the study

4.3. Clinical features

Dental pieces in ectopic inclusion do not always present specific symptoms, as is the situation of 4 of the studied cases, that is, 16%. However, in the remaining 84% of the cases, it is noted that when they induce a secondary infection or compress important anatomical structures, various symptoms may occur. Consequently, ectopic teeth in the maxillary sinus or nasal cavity compromised with various anatomical structures can cause: headache, nasal obstruction, runny nose, recurrent sinusitis, diffuse pain, bleeding, and in rare cases, as is the case when they are close to the nasolacrimal duct, they can cause: spontaneous tearing or intermittent mucoid secretion from the inner corner of the eye. On the other hand, those found in the condylar, subcondylar, or sigmoid region tend to cause: pain and inflammation in the preauricular region and trismus (Table 1).

4.4. Treatment

The therapeutic choice in 88% of these cases was surgical extraction, using an intraoral approach in almost all cases except one, in which an extraoral approach was performed. The results demonstrate that in surgical-dental practice a Caldwell-Luc approach is preferred for maxillary sinus access.

In the remaining 12%, it was decided to refrain from performing surgical extraction, one of these cases mentions that a follow-up control was carried out at 6 months, another case reported annual clinical-radiographic control, while the remaining case does not specify the control time. (Table 1).

4.5. Associated injuries.

From the 25 ectopic dental inclusions, 40% presented histopathologically confirmed dentigerous cyst, 16% associated with granuloma, 28% had normal follicular space, the associated lesion was not mentioned in 12% of teeth in ectopic dental inclusion and was recorded in a 4% to a case associated with radicular cyst (Table 1).

4.6. Demographic data age and gender

Table 2 Most affected population according to genre and age group

	Genre		Age			
	Female	Male	<15 years old	16-30 years old	31-45 years old	>46 years old
Cases number	17	8	1	10	6	8
Percentage	68.00%	32.00%	4.00%	40.00%	24.00%	32.00%

The 25 case reports mentioned the age of the patients, a wide age range was found that goes from 11 to 70 years, the average age of cases analyzed is 36.92 years, being the third decade of life in which this disease is diagnosed. This is

because they are generally diagnosed by clinical findings or when they present symptoms typically associated with dentigerous cysts, a pathology characterized by slow progress, which can exist for several years without being noticed. The genre of the patients was also reported in all the articles reviewed, showing in this study a slight prevalence for the female genre, since 17 patients were women representing 68% and 8 men with 32% (Table 2).

5. Discussion

The relevant results of this literature review reveal several important aspects. In the first place, the dental group with the greatest affectation are the third molars in 68%, followed by the canines 12%, and unspecified molars 8%. On the other hand, the remaining 12% is comprised of the following ectopic teeth: the second premolar, central incisor and supernumerary.

According to our case study, 16% remain asymptomatic, while ectopic teeth included in the maxillary sinus or nasal cavity can cause various symptoms such as headache, nasal obstruction and runny nose, among others, on the other hand, those found in the condylar, subcondylar, or sigmoid region can cause: pain and edema in the preauricular region or trismus. An 88% of the cases were treated by surgical extraction, choosing an intraoral approach in almost all cases except one in which an extraoral approach was performed, the remaining 12% gave up surgery, opting for annual radiographic clinical follow-up.

In support of these results, Lombrogni (7) specifies that most of his patients presented sinusitis or purulent rhinorrhea, swelling, localized pain and headache, although it was also possible to find in other patients' symptoms that are unexpected as cases of hypoaesthesia of the infraorbital nerve, facial fullness, epiphora and hemoptysis. On the other hand, in relation to ectopic teeth associated with infections, there are cases of oroantral fistulae and purulent discharge (7).

In a study conducted by Iglesias et al. (18), only molars included in the lower jaw were analyzed and it was concluded that the location in the subcondylar or condylar region is the most common site of ectopic lower third molars, which coincides with the results of this study, because no other dental piece presents as much predisposition as the third molar in that region of the lower jaw.

The differential diagnosis of ectopic teeth in the maxillary sinus includes infections such as: tuberculosis, syphilis or fungal infections with calcification, benign lesions such as hemangioma, osteoma, calcified polyp, enchondroma, foreign bodies (rhinoliths) and malignant lesions such as osteosarcoma and chondrosarcoma must be taken into account (19).

In relation to risk factors, it is considered by several authors as a multifactorial pathology. Lombrogni (7) suggests developmental alterations such as: cleft palate, trauma, previous rhinogenic or odontogenic infections, genetic factors, crowding or dentigerous cysts surrounding the included tooth. In support of this finding, Helm (10) specifies that patients with cleft lip and palate have a four times greater predisposition to develop ectopic dental inclusion, making it clear that the genetic component is a risk factor to consider (7, 10).

In the bibliographic review carried out by Buyukkurt et al. (25), found that the incidence of associated ectopic teeth is slightly higher in men compared to women, in contrast, our study showed a slight prevalence for females.

Finally, the treatment of choice for an ectopic tooth will be surgical removal by means of an intraoral approach whenever possible, instead, Kim et al. (31), mentions that the abstentionist position with periodic reviews is appropriate when the patient is elderly and, there are no symptoms or evidence of cystic lesion. On the other hand, Caillet et al. (20), indicates that for teeth located in the condyle, the preferred approach is extraoral, which is consistent with our findings in this review.

6. Conclusion

Ectopic dental inclusion is a dental clinical entity characterized by the displacement and retention of a dental piece in an irregular location and position, the dental group with the highest incidence is the third molar. The etiology remains unknown as it is associated with several factors. The prevalence in relation to genre results in a slight predilection for female, while the most common age range of its diagnosis is the third decade of life. Treatment for a patient with ectopic dental inclusion differs depending on their presentation characteristics, but is usually resolved by intraoral surgical approach (Caldwell - Luc approach or circumvestibular approach), the intervention must be carefully planned

understanding the potential risk, possible complications and the benefits by prioritizing a conservative surgical technique that causes minimal trauma to patients.

Compliance with ethical standards

Acknowledgments

The authors thank their family who have supported their studies and their academic training, as well as their tutor who has guided them during the execution of this article.

Disclosure of conflict of interest

There are no conflicts of interest in this work.

References

- [1] Caliskan S, Tuloglu N, Ozdemir C, Kizilaslan S, Bayrak S. Ectopic eruption of maxillary permanent first molars: Predictive factors for self-corrected and impacted outcome. *Int J Clin Pract*. 2021 Mar, 75(3).
- [2] Daimi SRH. Bilateral Ectopic Eruption of a Maxillary Third Molar Tooth from the Infratemporal Surface of the Maxilla in a Dry Human Skull. *International journal of applied & basic medical research*. 2020, 10(2).
- [3] Aldowsari MK, Alsaidan M, Alaqil M, BinAjian A, Albeialy J, Alraawi M, et al. Ectopic Eruption of First Permanent Molars for Pediatric Patients Attended King Saud University, Riyadh, Saudi Arabia: A Radiographic Study. *Clinical, cosmetic and investigational dentistry*. 2021 Jul 24, 13.
- [4] García-Rosas BL, Gutierrez-Rojo JF. Frequency of dental anomalies in patients of the Orthodontics Specialty of the UAN clinic. *Rev Tame*. 2021 Jul 8, 8.9(24):974–7.
- [5] Wu Y, Song Y, Huang R, Hu J, He X, Wang Y, Zhou G, Sun C, Jiang H, Cheng J, Wang D. Comprehensive analysis of ectopic mandibular third molar: a rare clinical entity revisited. *Head Face Med*. 2017 Dec 11, 13(1):24.
- [6] Hwang S, Choi YJ, Lee JY, Chung C, Kim KH. Ectopic eruption of the maxillary second molar: Predictive factors. *Angle Orthod [Internet]*. 2017 Jul [cited 2022 Jan 24], 87(4).
- [7] Lombroni LG, Farronato G, Santamaria G, Lombroni DM, Gatti P, Capelli M. Ectopic teeth in the maxillary sinus: A case report and literature review. *Indian J Dent Res [Internet]*. 2018 [cited 2022 Jan 23], 29(5).
- [8] Alberto PL. Surgical Exposure of Impacted Teeth. *Oral Maxillofac Surg Clin North Am [Internet]*. 2020 Nov [cited 2022 Jan 24], 32(4).
- [9] Kaczor-Urbanowicz K, Zadurska M, Czochrowska E. Impacted Teeth: An Interdisciplinary Perspective. *Adv Clin Exp Med [Internet]*. 2016 [cited 2022 Jan 24], 25(3).
- [10] Helm A, Martín-Vacas A, Molinero-Mourelle P, Caleyá AM, Gallardo NE, Mourelle-Martínez MR. Ectopic Eruption of Maxillary First Permanent Molars: Preliminary Results of Prevalence and Dentoskeletal Characteristics in Spanish Paediatric Population. *Children [Internet]*. 2021 Jun 6 [cited 2022 Jan 24], 8(6).
- [11] Veerabhadrappe SK, Hesarghatta RP, Yadav S, At BZ. Analysis of clinical characteristics and management of ectopic third molars in the mandibular jaw: a systematic review of clinical cases. *Acta Odontol Scand [Internet]*. 2021 Oct [cited 2022 Jan 8], 79(7).
- [12] Twyana R, Khanal P, Chaudhary B, Sagtani A, Gupta S. Knowledge of Impacted Teeth among the Undergraduate Dental Students of a Medical College: A Descriptive Cross-Sectional Study. *JNMA J Nepal Med Assoc [Internet]*. 2021 Jul 30 [cited 2022 Jan 23], 59(239).
- [13] Yang P, Liang H, Zou B, Liu J, Yuan D, Meng Z, et al. Ectopic tooth in maxillary sinus compressing the nasolacrimal canal: A case report. *Medicine [Internet]*. 2021 May 7 [cited 2022 Jan 24], 100(18).
- [14] Ray B, Bandyopadhyay SN, Das D, Adhikary B. A rare cause of nasolacrimal duct obstruction: Dentigerous cyst in the maxillary sinus. *Indian J Ophthalmol*. 2009, 57(6):465.
- [15] Antunes Freitas D, Vergara Hernández CI, Díaz Caballero A, Comino Mol V. Dentigerous cyst associated with an ectopic tooth in the maxillary sinus: A case report and review of the literature. *J Odontostomatol*. 2011, 27(6):283–8.

- [16] Moreno García C, Collado López J, Monje Gil F, Serrano Gil H, Morillo Sánchez AJ, Mateo Arias J, et al. Ectopic third molar at the level of the infraorbital region-maxillary sinus. *J Cirug Oral y Maxilofac*. 2007, 29(3):173–7.
- [17] Campos AU, Villasana JEM, González DAA, Ramirez LAC. Heterotopic third molar in the orbital rim: A case report and literature review. *ADM*. 2019 Oct 31, 76(5):287–93.
- [18] Iglesias-Martin F, Infante-Cossio P, Torres-Carranza E, Prats-Golczer V-E, Garcia-Perla-Garcia A. Ectopic third molar in the mandibular condyle: A review of the literature. *Medicina Oral, Patología Oral y Cirugía Bucal*. 2012 Nov, 17(6):e1013.
- [19] Almomen A, Alkhudair B, Alkhatib A, Alazzah G, Ali Z, Al Yaeesh I, et al. Ectopic maxillary tooth as a cause of recurrent maxillary sinusitis: a case report and review of the literature. *Journal of Surgical Case Reports [Internet]*. 2020 Sep [cited 2022 Jan 24], 2020(9).
- [20] Caillet J, Pereira B, Courtot R, Barthélémy I, Devoize L, Depeyre A. Ectopic third mandibular molar: evaluation of surgical practices and meta-analysis. *Clin Oral Investig*. 2021 Jun 17, 25(8):4781–99
- [21] Delys Fernandez RE, Jiménez Rodríguez Y, Coca Granados R. Heterotopic third molar in the right mandibular condyle associated with a dentigerous cyst. *Electronic Medical Center*. 2013, 17(2):79–82.
- [22] Mohan S, Kankariya H, Harjani B, Sharma H. Ectopic third molar in the maxillary sinus. *Natl J Maxillofac Surg*. 2011, 2(2):222
- [23] Ismail MQ, Lauridsen E, Andreasen JO, Hermann NV. Ectopic eruption of the second premolar: an analysis of four different treatment approaches. *Eur Arch Paediatr Dent [Internet]*. 2020 Feb [cited 2022 Jan 23], 21(1).
- [24] Ruiz VCA, Fragozo MJF, Rivera GAM. Modified endaural approach for the temporomandibular joint: 20 years of experience. Description of the surgical technique. *Cir Bucal Maxilofac*. 2014, 10 (3):116-121.
- [25] Buyukkurt MC, Omezli MM, Miloglu O. Dentigerous cyst associated with an ectopic tooth in the maxillary sinus: a report of 3 cases and review of the literature. *Oral Surg Oral Med Oral Pathol Oral Radiol Endod [Internet]*. 2010 Jan [cited 2022 Jul 8], 109(1).
- [26] Okuyama K, Sakamoto Y, Naruse T, Kawakita A, Yanamoto S, Furukawa K, et al. Intraoral extraction of an ectopic mandibular third molar detected in the subcondylar region without a pathological cause: A case report and literature review. *Cranio [Internet]*. 2017 Sep [cited 2022 Jan 24], 35(5).
- [27] Hanisch M, Fröhlich LF, Kleinheinz J. Ectopic third molars in the sigmoid notch: etiology, diagnostic imaging and treatment options. *Head Face Med [Internet]*. 2016 [cited 2022 Jan 24], 12.
- [28] Findik Y, Baykul T. Ectopic third molar in the mandibular sigmoid notch: Report of a case and literature review. *J Clin Exp Dent*. 2015 Feb 1, 7(1): e133-7. doi: 10.4317/jced.51871. PMID: 25810825, PMCID: PMC4368001.
- [29] Buchanan MA, Prince SE, Prinsley PR. Frontal mucocele caused by an ectopic maxillary tooth. *J Laryngol Otol [Internet]*. 2008 Dec [cited 2022 Jan 24], 122(12).
- [30] Ramanojam S, Halli R, Hebbale M, Bhardwaj S. Ectopic tooth in maxillary sinus: Case series. *Ann Maxillofac Surg*. 2013, 3(1):89.
- [31] Kim JS. Cone beam computed tomography findings of ectopic mandibular third molar in the mandibular condyle: report of a case. *Imaging Sci Dent*. 2011 Sep, 41(3):135-7. doi: 10.5624/isd.2011.41.3.135. Epub 2011 Sep 15. PMID: 22010071, PMCID: PMC3189538.
- [32] Sanchis JM, Murillo J, Diaz JM, Sanchis JC. Ectopic mandibular third molar in the subcondylar region: clinical case and review of the literature. *J Cirug Oral y Maxilofac*. 2016, 38(3):176–80.
- [33] Del Pilar Albarracin-Garcia A, Muñoz LF, Albarracin-García GE. Extraction of ectopic tooth in communication with the floor of the nasal cavity: case report. *Ustasalud*. 2020 Oct 20, 19:35–41.
- [34] Cazar MA, Palacios DEV, Torres YJC, Miranda JEV. Ectopic third molar in the maxillary sinus: a case report. *J ADM*. 2017 Sep 1, 74(4):202–205.
- [35] Lizama Fernandez, C., Lizama Velasco, J. Maxillary sinusitis of odontogenic cause. Literature review. About a case. *J Cient. Dent*. 2014, 11, 2: 151-156.
- [36] D. Duran Barata, B. Pintado Cort, C. Rodríguez Calle, R. Nieto Royo, I. Cano Pumarega, C. Almonacid Sánchez. COVID is not all that glitters. *J Patol Respir*. 2021, 24(2): 83-85
- [37] De Bortoli MM, de Arruda JAA, Vasconcellos RJH, Silva EDO, de Medeiros Tormes AK, Moreno A, et al. Surgical treatment for a rare case of ectopic tooth in the lateral wall of the nasal cavity. *Arch Health Invest [Internet]*. 2019 [cited 2022 Feb 17], 8(11).