

UCUENCA

Universidad de Cuenca

Facultad de Odontología

Carrera de Odontología

Sinusitis de origen odontogénico, diagnostico diferencial: Revisión de literatura

Trabajo de titulación previo a la
obtención del título de Odontólogo

Autores:

Micaela Salome Cordero Morales

Paula Michelle Correa Brito

Director:

David Manuel Pineda Álvarez

ORCID: 0000-0002-6395-7702

Cuenca, Ecuador

2023-10-06

Resumen

Objetivo: Analizar la importancia de realizar un buen diagnóstico de la sinusitis de origen odontogénico, mediante la búsqueda en diferentes bases digitales. **Metodología:** Se realizó bibliográfica en las bases de datos Pubmed y Scopus de estudios publicados entre 2017-2022 haciendo uso de las palabras claves, además se utilizó el operador Booleano AND para la unión entre estos descriptores y se realizaron las preguntas de indagación basado en la abreviatura PICO. **Resultados:** Se obtuvieron 1270 estudios entre las dos bases digitales de estos 50 fueron los seleccionados después de aplicar criterios de exclusión e inclusión. **Conclusión:** La sinusitis odontogénica debe presentar un diagnóstico multidisciplinario Odontólogo-Otorrinolaringólogo. Los focos odontogénicos más frecuentes son patologías periapicales, cirugías previas, molares que están en cercanía al piso del seno maxilar. Se debe tomar en cuenta síntomas y estudios radiográficos como la CBCT.

Palabras clave: sinusitis odontogénica, sinusitis maxilar, diagnóstico, examen clínico, radiografía



El contenido de esta obra corresponde al derecho de expresión de los autores y no compromete el pensamiento institucional de la Universidad de Cuenca ni desata su responsabilidad frente a terceros. Los autores asumen la responsabilidad por la propiedad intelectual y los derechos de autor.

Repositorio Institucional: <https://dspace.ucuenca.edu.ec>

Abstract

Objective: To analyze the importance of making a good diagnosis of sinusitis of odontogenic origin, by means of a search in different digital databases. **Methodology:** A bibliographic search was performed in the Pubmed and Scopus databases of studies published between 2017-2022 using keywords, in addition, the Boolean operator AND was used for the union between these descriptors and the inquiry questions were asked based on the abbreviation PICO. **Results:** 1270 studies were obtained between the two digital databases, of which 50 were selected after applying exclusion and inclusion criteria. **Conclusion:** Odontogenic sinusitis should be diagnosed by a multidisciplinary Odontologist-Otorhinolaryngologist. The most frequent odontogenic foci are periapical pathologies, previous surgeries, molars that are close to the floor of the maxillary sinus. Symptoms and radiographic studies such as CBCT should be taken into account.

Keywords: odontogenic sinusitis, maxillary sinusitis, diagnosis, clinical examination, radiography



The content of this work corresponds to the right of expression of the authors and does not compromise the institutional thinking of the University of Cuenca, nor does it release its responsibility before third parties. The authors assume responsibility for the intellectual property and copyrights.

Institutional Repository: <https://dspace.ucuenca.edu.ec/>

Índice

1. Introduction	6
2. Material and methods	8
3. Procedure	9
4. Results	9
5. Discussion	11
6. Conclusion	14
7. References	15

Índice de figuras

Figura 1. Diagrama de flujo de búsqueda de literatura para revisión de sinusitis de origen odontogénico 10

1. Introduction

The first paranasal sinus to develop within fetal life is the maxillary sinus, which reaches its full development when the individual reaches 12 to 14 years of age, which coincides with the eruption of permanent teeth (1). The floor of the maxillary sinus is very close to the roots of the second maxillary molars, and it is connected to the nasal cavity by the ostium, and it is made up of thick cortical bone, but with age, its thickness reduces, resulting in a layer known as Schneider's mucosa, which implies a direct penetration of odontogenic infections. This is why any disease of dental or dentoalveolar origin could damage it and cause a case of sinusitis known as odontogenic maxillary sinusitis. It is likely that the incidence of SOM has been underreported, with 10-12% of OME cases attributed to odontogenic infections (1 3).

Odontogenic sinusitis might be multifactorial. Among these facts, it shows the iatrogenic, infectious, traumatic, and implantological causes (4). Therefore, the principal cause of this fact is related to the dental extractions. Some studies have shown that the iatrogenic etiology represents 65.7%. This percentage includes the artificial implants and the oroantral fistula formation post-dentoalveolar surgery (1,5). The odontogenic sinusitis might be located and manifest itself as a thickening of the mucous membrane in the maxillary sinus, restricted only to the vicinity of the infected tooth (3).

Odontogenic sinusitis is considered a polymicrobial infection since bacteria from the oral cavity and respiratory system are involved (6). Psila et al. (1) state that the bacterial anaerobic flora is the main cause of chronic odontogenic sinusitis; however, the bacterial flora of some patients that present acute sinusitis is of mixed origin.

The organic causes include dental cavities and periodontal diseases that lead to a secondary infection of the dental pulp (1,7). Some patients present symptoms similar to chronic rhinosinusitis, such as dental pain, nasal congestion, and unilateral nasal obstruction, while others present minimal symptoms of sinusitis and dental pain because the osteomata complex is unobstructed and allows drainage and relief of pressure (4,5). The chronical maxillary sinusitis occurs more often unilaterally. However, in severe sinusitis cases, this fact becomes stronger,

UCUENCA

meaning that a dental etiology might represent up to 86% of the cases (8,9). The etiology, pathophysiology, diagnosis, and treatment differ from other types of sinusitis, while the clinic symptoms are not proven (10).

This review aims to present the methods to do an accurate diagnostic of odontogenic sinusitis, in which both the otolaryngologist and the dentist are in charge of doing it in the first instance, with the purpose of being able to provide an effective treatment that helps us obtain valuable long-term results.

2. Metodology

Based on the objectives previously stated, a literature review was held following the recommendations of the PICO system.

2.1. Searching Strategies

The search tools for this investigation were PubMed and SCOPUS. In order to connect these two descriptors, the Booleano ADN was used. The key words for this research are interconnected with the objectives previously stated, according to the terms MeSH and DeCs: "odontogenic sinusitis", "diagnostic", "clinical exam" and "bone scan," which are their translations into English.

2.2. Inclusive and exclusive criteria

2.2.1. Inclusion Criteria

- Written papers in any language
- Studies published between the years 2017-2022
- The literature review of the sinusitis has to be of odontogenic origin.
- The systematic review of the sinusitis has to be of odontogenic origin.
- The metanalysis of sinusitis has to be of odontogenic origin.

2.2.2. Exclusion Criteria

- Literature review which does not accomplish the inclusive criteria.
- Some sections of books have been excluded.

3. Procedure

The literature review considers four stages: First, the topic was pre-established, and the inquiry questions based on the abbreviation PICO (Question, Intervention, Comparison, and Outcome) were done. These questions are: "What is the relevance of the precise diagnosis of odontogenic sinusitis?" and "How to do a correct diagnosis?" Second, inclusive and exclusive criteria were established. Third, complete studies were examined, in which original articles related to odontogenic sinusitis were included. These articles were published in English and Spanish with complete and free access texts; studies such as clinical cases, theses, monographs and articles with restricted access were excluded. Fourth, the drafting of this article was done based on the literature review pre-selected with the outstanding topic.

4. Results

Figure 1 shows the flowchart of the literature review. Several digital databases, such as PubMed and Scopus, were reviewed, and a total of 1270 studies were obtained. Due to the large quantity and quality of studies attained, their totals were filtered by exclusive and inclusive criteria. 658 articles were excluded due to duplicity and 543 due to title reading and lack of free access, obtaining a total of 67 articles chosen for the complete analysis and 17 excluded articles. Finally, 50 articles were obtained for the corresponding literature review.

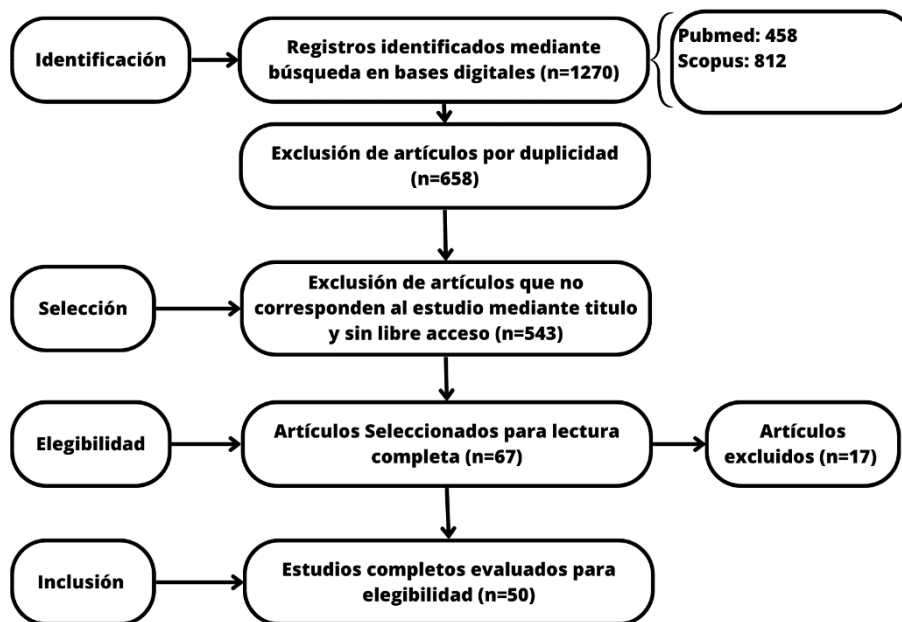


Figure 1 Search flowchart for the literature review of sinusitis of odontogenic origin

5. Discussion

Odontogenic sinusitis (OS) is the only type of maxillary sinusitis of dental origin to which special attention should be paid. Both the otolaryngologists and the dentist ought to work hand in hand to make an accurate diagnosis of the origin of sinusitis and its favorable long-term treatment. An accurate diagnosis of sinusitis of odontogenic origin is obtained when the sinuses are meticulously evaluated in the radiographic, microbiological, and clinical fields and when the results show a similar disease of dental origin (11).

Unilateral maxillary sinusitis is also called odontogenic sinusitis due to the symptomatology that it presents. Ryan et al (12) pointed out that 10% of the chronic maxillary sinusitis cases present an odontogenic origin, but this percentage might achieve up to 75% of the cases that present a unilateral maxillary disease in comparison to a study held by Fredriksson et al (13), who obtained a result of 14 out of 35 unimaxillary sinusitis cases meaning that 40% presented odontogenic causes.

From all the results of chronic sinusitis maxillary cases, studies reported that from 10% to 40% of them were the result of an odontogenic procedure (12, 14). However, other causes of odontogenic sinusitis are iatrogenic during the development of dental procedures; for instance, root canals, dental surgery, periapical pathology, and the placement of dental implants. Ryan et al (12) agreed with Ben-Zvi et al and Bajoria et al (15, 16) that almost 50% of patients with OS mentioned that they had previously undergone dental surgery, compared to those studies made by Sato K, Roderick et al, Lima et al and Peñarrocha et al (17-20), in which they agreed that the patients presented a root canal done previously. Czarnecka et al (21) detected odontogenic foci in 85.7% of patients after an inadequate endodontic treatment; 13% were retained roots; 91% showed inflammatory states in the periodontium visible on radiographs; and 7.4% were impacted teeth. On the other hand, Craig et al (22) differed in that 63% of the cases were caused by apical periodontitis and 80% by molars. Contreras and Cebrian (23) added extravasation of filling material into the sinus after doing a root canal, amalgam remains after an apicoectomy, migration of implants in the maxillary sinus, sinus lift surgery, facial trauma, orthognathic surgery, or cleft palate surgery.

UCUENCA

Many patients were diagnosed with OS in a condition that does not meet any specific criteria for this condition. This fact occurs because there are no shared diagnoses because the OS is considered different from rhinosinusitis from an etiological, microbiological, and even radiological point of view. Consequently, this condition may cause problems at the moment of deciding which therapy should be carried out in that situation and its results (24). While rhinosinusitis belongs to the field of otolaryngology, odontogenic maxillary sinusitis is a pathology explored by both otolaryngologists and oral and maxillofacial dentists and surgeons (25).

Marta Kwiatkowsk et al, Cristian Martu et al and Allevi et al (24, 26–27) point out that odontogenic sinusitis is underdiagnosed because it does not present specific symptoms; however, among the prominent symptoms are: rhinorrhea, postnasal drip, nasal congestion, dental pain, facial pain, fatigue, hyposmia, and bad breath. On the other side, Rokas Aukštakalni et al (28) show in their study that there are three principal symptoms of the OS, which are: facial pain, postnasal discharge, and congestion. Nevertheless, Ryan et al (12) indicate that the presence of dental pain is not a specific symptom of odontogenic sinusitis since, in many cases, this symptom is not usually described by patients. Finally, a lot of studies show that bad smelling rhinorrhea (cacosmia) is considered a specific symptom of OS in comparison to acute or chronic maxillary sinusitis (29). Moreover, Whyte and Boeddinghaus (30) state that for the maxillary sinusitis diagnosis, two or more key symptoms should show up during at least 12 weeks.

Odontogenic infections are considered polymicrobial. It means that there are aerobic and anaerobic families with a predominance of anaerobes (31). Martu et al (27) concluded that the flora of the acute OS is aerobic, while in the chronic OS, it is anaerobes (Gram negative bacilli). Roderick et al and Min and Kim (18, 32) agree with them because for them there is a slight predominance of anaerobes, the species being *Prevotella*, *Fusobacterium*, and *Peptococcus*, which are the most commonly isolated, and among the aerobic bacteria, β -hemolytic streptococcal species of the viridans group were especially prevalent. McCormick et al (33) point out that any dental procedure that penetrates through the epithelial lining of the sinus may allow the proliferation of fungal species. Whyte and Boeddinghaus (30) disagree that the common pathogenic bacteria are the aerobic ones of respiratory origin.

UCUENCA

Oral health professionals should make use of adequate image exams to obtain results that help confirm the pathology of paranasal sinuses because a simple radiographic exam like periapical radiography or a panoramic one is not enough to obtain an accurate diagnosis of OS (34, 35). For Saibene et al, Dobroy and Zarzecka, and Kim et al (36–38), computed tomography (CT) and cone beam CT (CBCT) are the most commonly used tools to diagnose sinusitis and identify the dental problem. The study of the maxillofacial region has been revolutionized with the use of high-resolution multiplanar CBCT (39, 40), which is why cone beam tomography has been used for the evaluation of paranasal sinuses in order that the vision in both the axial and coronal angles allows us to observe the maxillary sinus in relation to some periapical pathology or a sinus floor defect (1, 41). Oleg et al, Goyal et al, Kim et al (42–44) stated in their study that the principal radiographic signs of odontogenic sinusitis were: thickened mucosa, unilateral maxillary sinus opacification, with or without other sinus involvement, and presence of fluid levels. Moreover, Bisla et al (45) added an extra finding: sinus polyps in 7.2%. Oleg et al and Don Ly & Johan (42, 46) mentioned that through the use of CT and its combination with an oral clinical exam, they obtained an accurate diagnosis of odontogenic sinusitis. 70% of cases of odontogenic sinusitis have been diagnosed using this method.

Authors like Mahasneh et al, Abrams, and Bajoria et al (16, 35, 41) manifest that the rear teeth, such as the molars, and their periapical disease present a close relationship with the causes of the perforation of the floor of the maxillary sinus, resulting in the presence of OS. On the other hand, Kodur et al, Sakir et al and Schreindorfer et al (31, 47, 48) consider that the second molars with all their roots are the teeth closest to the floor of the sinus. This is followed by the second premolar, and finally by the first premolar. However, only the palatal roots of the first maxillary molars and the mesiobuccally roots of the second molars present a direct association with the appearance of odontogenic sinusitis; likewise, the causes of odontogenic sinusitis are the molars, followed by the premolars, incisors, and canines (49, 50).

6. Conclusion

Odontogenic sinusitis should present a multidisciplinary diagnosis in which a joint diagnosis is carried out, that is, an otorhinolaryngologist-otorhinolaryngologist, in which clinical, radiological, and microbiological aspects should be taken into account. The most frequent odontogenic focal points are periapical pathologies, former surgeries, and molars that are close to the floor of the maxillary sinus. The OS symptomatology is not yet specifically recognized; nonetheless, the main symptoms are facial pain, postnasal discharge, and congestion; the only specific symptom is the bad smell of rhinorrhea; as well as taking into consideration radiographic methods, such as the CBCT, which allows to examine the maxillary sinus in relation to a periapical pathology or a sinus floor defect.

7. References

Psillas G, Papaioannou D, Petsali S, Dimas GG, Constantinidis J. Odontogenic maxillary sinusitis: A comprehensive review. Vol. 16, *Journal of Dental Sciences*. Association for Dental Sciences of the Republic of China; 2021. p. 474–81.

Kim SM. Definition and management of odontogenic maxillary sinusitis. Vol. 41, *Maxillofacial Plastic and Reconstructive Surgery*. Springer Science and Business Media Deutschland GmbH; 2019.

Kuligowski P, Jaroń A, Preuss O, Gabrysz-Trybek E, Bładowska J, Trybek G. Association between odontogenic and maxillary sinus conditions: A retrospective cone-beam computed tomographic study. *J Clin Med*. 2021 Jul 1;10(13).

Zirk M, Dreiseidler T, Pohl M, Rothamel D, Buller J, Peters F, et al. Odontogenic sinusitis maxillaris: A retrospective study of 121 cases with surgical intervention. *Journal of Cranio-Maxillofacial Surgery*. 2017 Apr 1;45(4):520–5.

Workman AD, Granquist EJ, Adappa ND. Odontogenic sinusitis: Developments in diagnosis, microbiology, and treatment. Vol. 26, *Current Opinion in Otolaryngology and Head and Neck Surgery*. Lippincott Williams and Wilkins; 2018. p. 27–33.

Taschieri S, Torretta S, Corbella S, del Fabbro M, Francetti L, Lolato A, et al. Pathophysiology of sinusitis of odontogenic origin. Vol. 8, *Journal of investigative and clinical dentistry*. 2017.

Raman A, Papagiannopoulos P, Kuhar HN, Gattuso P, Batra PS, Tajudeen BA. Histopathologic Features of Chronic Sinusitis Precipitated by Odontogenic Infection. *Am J Rhinol Allergy*. 2019 Mar 1;33(2):113–20.

Craig JR, Poetker DM, Aksoy U, Allevi F, Biglioli F, Cha BY, et al. Diagnosing odontogenic sinusitis: An international multidisciplinary consensus statement. Vol. 11, *International Forum of Allergy and Rhinology*. John Wiley and Sons Inc; 2021. p. 1235–48.

Siqueira JF, Lenzi R, Hernández S, Alberdi JC, Martin G, Pessotti VP, et al. Effects of Endodontic Infections on the Maxillary Sinus: A Case Series of Treatment Outcome. *J Endod*. 2021 Jul 1;47(7):1166–76.

Simuntis R, Kubilius R, Padervinskis E, Ryškienė S, Tušas P, Vaitkus S. Clinical efficacy of main radiological diagnostic methods for odontogenic maxillary sinusitis. *European Archives of Oto-Rhino-Laryngology*. 2017 Oct 1;274(10):3651–8.

Molteni M, Bulfamante AM, Pipolo C, Lozza P, Allevi F, Pisani A, et al. Odontogenic sinusitis and sinonasal complications of dental treatments: A retrospective case series of 480 patients with critical assessment of the current classification. *Acta Otorhinolaryngologica Italica*. 2020 Aug 1;40(4):282–9.

Little RE, Long CM, Loehrl TA, Poetker DM. Odontogenic sinusitis: A review of the current literature. Vol. 3, *Laryngoscope Investigative Otolaryngology*. John Wiley and Sons Inc; 2018. p. 110–4.

Vestin Fredriksson M, Öhman A, Flygare L, Tano K. When Maxillary Sinusitis Does Not Heal: Findings on CBCT Scans of the Sinuses With a Particular Focus on the Occurrence of Odontogenic Causes of Maxillary Sinusitis. *Laryngoscope Investig Otolaryngol*. 2017;2(6):442–6.

Craig JR, Tataryn RW, Aghaloo TL, Pokorny AT, Gray ST, Mattos JL, et al. Management of odontogenic sinusitis: multidisciplinary consensus statement. Vol. 10, *International Forum of Allergy and Rhinology*. John Wiley and Sons Inc.; 2020. p. 901–12.

Ben-Zvi Y, Rosenfeld E, Masri D, Avishai G, Chaushu G, Chaushu L. Clinical and radiological characteristics of oro-antral communications/fistulae due to implant dentistry procedures: A cross-sectional retrospective study. *Clin Implant Dent Relat Res*. 2021 Feb 1;23(1):54–60.

Bajoria AA, Sarkar S, Sinha P. Evaluation of odontogenic maxillary sinusitis with cone beam computed tomography: A retrospective study with review of literature. Vol. 9, *Journal of International Society of Preventive and Community Dentistry*. Wolters Kluwer (UK) Ltd.; 2019. p. 194–204.

Sato K, Chitose S ichi, Sato K, Sato F, Ono T, Umeno H. Pathophysiology of current odontogenic maxillary sinusitis and endoscopic sinus surgery preceding dental treatment. *Auris Nasus Larynx*. 2021 Feb 1;48(1):104–9.

Craig JR, Tataryn RW, Cha BY, Bhargava P, Pokorny A, Gray ST, et al. Diagnosing odontogenic sinusitis of endodontic origin: A multidisciplinary literature review. Vol. 42, *American Journal of Otolaryngology - Head and Neck Medicine and Surgery*. W.B. Saunders; 2021.

de Lima CO, Devito KL, Baraky Vasconcelos LR, Prado M do, Campos CN. Correlation between Endodontic Infection and Periodontal Disease and Their Association with Chronic Sinusitis: A Clinical-tomographic Study. *J Endod*. 2017 Dec 1;43(12):1978–83.

Peñarrocha-Oltra S, Soto-Peñaloza D, Bagán-Debón L, Bagán-Sebastián J v., Peñarrocha-Oltra D. Association between maxillary sinus pathology and odontogenic lesions in patients evaluated by cone beam computed tomography. A systematic review and meta-analysis. Vol. 25, *Medicina Oral Patologia Oral y Cirugia Bucal*. Medicina Oral S.L.; 2020. p. e34–48.

Czarnecka P, Rutkowska M, Popecki P, Grodoń G. Przewlekłe zębopochodne zapalenie zatok przynosowych w materiale poradni otolaryngologicznej 4. Wojskowego szpitala klinicznego we Wrocławiu. *Dent Med Probl*. 2017 Jan 1;54(1):29–34.

Craig JR, Cheema AJ, Dunn RT, Vemuri S, Peterson EL. Extrasinus Complications From Odontogenic Sinusitis: A Systematic Review. Vol. 166, *Otolaryngology - Head and Neck Surgery (United States)*. SAGE Publications Inc.; 2022. p. 623–32.

de Caso P, Contreras AM, Luis J, Carretero C. Órgano Oficial de la Sociedad Cubana de Ciencias Estomatológicas Sinusitis maxilar iatrogénica por material de impresión dental Iatrogenic maxillary sinusitis by dental impression material [Internet]. Available from: <http://www.revestomatologia.sld.cu/index.php/est/article/view/2826>

Allevi F, Fadda GL, Rosso C, Martino F, Pipolo C, Cavallo G, et al. Diagnostic Criteria for Odontogenic Sinusitis: A Systematic Review. Vol. 35, *American Journal of Rhinology and Allergy*. SAGE Publications Inc.; 2021. p. 713–21.

Simuntis R, Vaitkus J, Kubilius R, Padervinskis E, Tušas P, Leketas M, et al. Comparison of Sino-Nasal Outcome Test 22 Symptom Scores in Rhinogenic and Odontogenic Sinusitis. *Am J Rhinol Allergy*. 2019 Jan 1;33(1):44–50.

Kwiatkowska MA, Szczygielski K, Chloupek A, Szczupak P, Jurkiewicz D. Clinical characteristics of odontogenic sinusitis with periapical lesions. *American Journal of Otolaryngology - Head and Neck Medicine and Surgery*. 2022 Mar 1;43(2).

Martu C, Martu MA, Maftei GA, Diaconu-popa DA, Radulescu L. Odontogenic Sinusitis: From Diagnosis to Treatment Possibilities—A Narrative Review of Recent Data. Vol. 12, *Diagnostics*. MDPI; 2022.

Aukštakalnis R, Simonavičiūtė R, Simuntis R. Treatment options for odontogenic maxillary sinusitis: a review. Vol. 20, *Stomatologija, Baltic Dental and Maxillofacial Journal*. 2018.

Newsome HA, Poetker DM. Odontogenic Sinusitis: Current Concepts in Diagnosis and Treatment. Vol. 40, *Immunology and Allergy Clinics of North America*. W.B. Saunders; 2020. p. 361–9.

Whyte A, Boeddinghaus R. Imaging of odontogenic sinusitis. Vol. 74, *Clinical Radiology*. W.B. Saunders Ltd; 2019. p. 503–16.

Kodur S, Kiran HY, Shivakumar AM. Odontogenic Fungal Maxillary Sinusitis: A Case Report of a Displaced Dental Foreign Body. *Indian Journal of Otolaryngology and Head and Neck Surgery*. 2019 Nov 1;71:1805–9.

Min HJ, Kim KS. Odontogenic Sinusitis-Associated Pott's Puffy Tumor: A Case Report and Literature Review. *Ear Nose Throat J*. 2022 May 1;101(4):NP186–8.

McCormick JP, Hicks MD, Grayson JW, Woodworth BA, Cho DY. Endoscopic Management of Maxillary Sinus Diseases of Dentoalveolar Origin. Vol. 32, *Oral and Maxillofacial Surgery Clinics of North America*. W.B. Saunders; 2020. p. 639–48.

Craig JR. Odontogenic sinusitis: A state-of-the-art review. Vol. 8, *World Journal of Otorhinolaryngology - Head and Neck Surgery*. John Wiley and Sons Inc; 2022. p. 8–15.

Abrams J. Sinusitis of dental origin. Vol. 100, *Laryngo- Rhino- Otologie*. Georg Thieme Verlag; 2021. p. 532–41.

Saibene AM, Pipolo C, Borloni R, Felisati G. Ent and dentist cooperation in the management of odontogenic sinusitis. A review. *Acta Otorhinolaryngologica Italica*. 2021;41:116–23.

Dobroś K, Zarzecka J. Application of cone-beam computed tomography in the diagnostics of maxillary sinusitis of odontogenic origin - two case reports. *Journal of Stomatology*. 2017;70(2):212–7.

Kim HG, Lee KM, Kim EJ, Lee JS. Improvement diagnostic accuracy of sinusitis recognition in paranasal sinus X-ray using multiple deep learning models. *Quant Imaging Med Surg*. 2019;9(6):942–51.

Whyte A, Boeddinghaus R. The maxillary sinus: Physiology, development and imaging anatomy. *Dentomaxillofacial Radiology*. 2019;48(8).

Ito K, Kondo T, Andreu-Arasa VC, Li B, Hirahara N, Muraoka H, et al. Quantitative assessment of the maxillary sinusitis using computed tomography texture analysis: odontogenic vs non-odontogenic etiology. *Oral Radiol*. 2022 Jul 1;38(3):315–24.

Mahasneh SA, Al-Hadidi A, Hassona Y, Sawair FA, Al-Nazer S, Bakain Y, et al. Maxillary Sinusitis of Odontogenic Origin: Prevalence among 3D Imaging—A Retrospective Study. *Applied Sciences (Switzerland)*. 2022 Mar 1;12(6).

Avrunin OG, Nosova Y v., Abdelhamid IY, Pavlov S v., Shushliapina NO, Wójcik W, et al. Possibilities of automated diagnostics of odontogenic sinusitis according to the computer tomography data. *Sensors (Switzerland)*. 2021 Feb 2;21(4):1–22.

Goyal VK, Ahmad A, Turfe Z, Peterson EI, Craig JR. Predicting Odontogenic Sinusitis in Unilateral Sinus Disease: A Prospective, Multivariate Analysis. *Am J Rhinol Allergy*. 2021 Mar 1;35(2):164–71.

Kim Y, Lee KJ, Sunwoo L, Choi D, Nam CM, Cho J, et al. Deep Learning in Diagnosis of Maxillary Sinusitis Using Conventional Radiography. *Invest Radiol*. 2019 Jan 1;54(1):7–15.

Bisla S, Gupta A, Singh H, Sehrawat A, Shukla S. Evaluation of relationship between odontogenic infections and maxillary sinus changes: A Cone Beam Computed Tomography-based study. *J Oral Biol Craniofac Res*. 2022 Sep 1;12(5):645–50.

Ly D, Hellgren J. Is dental evaluation considered in unilateral maxillary sinusitis? A retrospective case series. *Acta Odontol Scand*. 2018 Nov 17;76(8):600–4.

Schreindorfer K, Kiss Á, Marada G. Maxillary sinusitis as a diagnostic adverse finding of the dental cone-beam computed tomography study. *Orv Hetil*. 2017 Nov 1;158(44):1747–53.

Sakir M, Ercalik Yalcinkaya S. Associations between Periapical Health of Maxillary Molars and Mucosal Thickening of Maxillary Sinuses in Cone-beam Computed Tomographic Images: A Retrospective Study. *J Endod*. 2020 Mar 1;46(3):397–403.

UCUENCA

Shukairy MK, Burmeister C, Ko AB, Craig JR. Recognizing odontogenic sinusitis: A national survey of otolaryngology chief residents. *American Journal of Otolaryngology - Head and Neck Medicine and Surgery*. 2020 Nov 1;41(6).

Schreindorfer K, Kiss Á, Marada G. Maxillary sinusitis as a diagnostical adverse finding of the dental cone-beam computed tomography study. *Orv Hetil*. 2017 Nov 1;158(44):1747–53.