

UCUENCA

Universidad de Cuenca

Facultad de Odontología

Carrera de Odontología

OSTEONECROSIS RELACIONADA CON MEDICAMENTOS: REVISIÓN DE LA LITERATURA

Trabajo de titulación previo a la obtención del título de Odontólogo


Autores:

María Coralía Idrovo Campoverde

Erika Susana Bacuilima Ñauta

Director:

Juan Martín Pesántez Alvarado

ORCID:  0000-0003-4335-9163

Cuenca, Ecuador

2023 - 10 - 13

Resumen

Objetivo: El objetivo de este estudio es determinar cuál es el medicamento con mayor probabilidad de desarrollar osteonecrosis maxilar, la vía de administración, dosis y tiempo de tratamiento que conllevan mayor riesgo, y establecer estrategias de prevención adecuadas con el fin de proporcionar nuevos conocimientos para el manejo de pacientes que tienen riesgo o están desarrollando osteonecrosis de maxilares relacionada con medicamentos.

Material y métodos: Revisión de la literatura de los últimos 5 años en las bases de datos PubMed, ScienceDirect y Springerlink, usando los siguientes términos: osteonecrosis in dentistry, osteonecrosis of the jaws y drug related osteonecrosis of the jaws.

Resultados: Se obtuvieron 20662 artículos entre las tres bases digitales, después de aplicar criterios de exclusión e inclusión, se revisaron 51 artículos para la revisión de literatura.

Conclusión: MRONJ es una afección poco común pero potencialmente grave asociada con el uso prolongado de agentes antirresortivos y antiangiogénicos. Sin embargo, por la heterogeneidad de evidencia no se ha determinado con exactitud la vía de administración de mayor riesgo.

Palabras clave: antiangiogénicos, antirresortivos, bifosfonatos, denosumab, osteonecrosis de maxilares



El contenido de esta obra corresponde al derecho de expresión de los autores y no compromete el pensamiento institucional de la Universidad de Cuenca ni desata su responsabilidad frente a terceros. Los autores asumen la responsabilidad por la propiedad intelectual y los derechos de autor.

Repositorio Institucional: <https://dspace.ucuenca.edu.ec/>

Abstract

Objective: The aim of this study is to determine the most likely medication to develop osteonecrosis of the jaw, the route of administration, dose and treatment time that carry the greatest risk, and to establish appropriate prevention strategies in order to provide new knowledge for the management of patients who are at risk or that are developing medication-related osteonecrosis of the jaw.

Materials and methods: Literature review of the last 5 years in the databases PubMed, ScienceDirect and Springer Link, using the following terms: osteonecrosis in dentistry, osteonecrosis of the jaws and drug related osteonecrosis of the jaws.

Results: A total of 20,662 articles were obtained from the three digital databases; after applying exclusion and inclusion criteria, 51 articles were selected for the literature review.

Conclusion: MRONJ is a rare but potentially serious condition associated with prolonged use of antiresorptive and antiangiogenic agents. However, because of the heterogeneity of evidence, the administration route of greatest risk has not been accurately determined.

Keywords: antiangiogenic agents, antiresorptive, bisphosphonates, denosumab, osteonecrosis of the jaws



The content of this work corresponds to the right of expression of the authors and does not compromise the institutional thinking of the University of Cuenca, nor does it release its responsibility before third parties. The authors assume responsibility for the intellectual property and copyrights.

Institutional Repository: <https://dspace.ucuenca.edu.ec/>

Índice de contenido

1. Introducción	7
2. Materiales y métodos.....	9
3. Resultados.....	10
4. Discusión.....	20
5. Conclusión.....	22
6. Cumplimiento de normas éticas.....	23
7. Referencias.....	24

Índice de figuras

Figura 1. Diagrama de flujo de búsqueda de literatura.....	10
---	----

Índice de tablas

Tabla. 1 Clasificación y Estadificación del Avance de la Necrosis.....	8
Tabla. 2 Estrategias de búsqueda.....	9
Tabla. 3 Resumen de los estudios seleccionados para revisión de la literatura.....	11

1. Introduction

Medication-related osteonecrosis of the jaw, or MRONJ, is a rare but potentially serious condition that can occur after exposure to high doses of agents used to modify bone metabolism, such as bisphosphonates (BP), denosumab and angiogenesis inhibitors (1) (2) (3).

Both bisphosphonates and denosumab are drugs primarily used to reduce the risk of skeletal complications in patients with bone loss who have received long-term treatment for cancer, osteoporosis, and malignant bone diseases (1) (38).

Bisphosphonates are a group of inorganic pyrophosphate derivative drugs. According to their mechanism of action, they are divided into two large groups: first generation (non-nitrogenous) such as etidronate, clodronate and tiludronate; second and third generation (nitrogenous): alendronate, risedronate, ibandronate, pamidronate and zoledronic acid (1) (2) (20).

These drugs are composed of molecules that bind to hydroxyapatite binding sites on bone surfaces; at the same time, they bind to the farnesyl pyrophosphate synthase of the osteoclast's enzyme (osteoclast: cells responsible for the reabsorption of the bone matrix by releasing hydrolytic enzymes) which lead to their apoptosis. Without osteoclasts, there is no signal for bone matrix apposition by osteoblasts or angiogenesis stimuli, consequently the bone tissue becomes acellular and avascular with necrosis risk when exposed to the oral environment (1) (2) (16).

The bisphosphonates attachment to the bone structure leads to their high concentration, especially in areas of greater bone remodeling such as the maxillary and mandible bones, this is the reason why the apoptotic rate of osteoclasts is higher in these areas, increasing the risk of drug-associated osteonecrosis (2) (9).

Although BPs are the main pharmacological causes of osteonecrosis in the jaw, there are other frequently used drugs; called anti RANKL monoclonal antibodies that can cause the same adverse effect. One of these agents is Denosumab, a highly specific human IgG2 monoclonal antibody against receptor activator of nuclear factor κ B ligand (RANKL), which inhibits osteoclast activity, reduces resorption and increases bone density (1) (20) (10). In addition, MRONJ may also be associated with anticancer agents, including classical chemotherapy agents, angiogenesis inhibitors, and biologic immunomodulators (1) (4) (5).

The clinical symptoms are variable, from an asymptomatic process to local pain, presence of fistulas, ulceration, inflammatory reaction of soft tissues, dental mobility and exposure of necrotic bone; pain and infectious symptoms being the most frequent reported by patients (2).

For the diagnosis of MRONJ, the following aspects should be considered:

- Current or previous treatment with bisphosphonates, denosumab, or antiangiogenic therapy.
- An area of exposed bone or bone that can be probed through an intraoral or extraoral fistula and has persisted for more than 8 weeks.
- No history of mandible radiotherapy or metastatic disease of the maxillary bones (3) (11).

Once the diagnosis of MRONJ is confirmed, the AAOMS classification and staging system is used as a management guide (Table 1) (2) (51).

Table 1 Classification and Staging of the Advancement of Necrosis

Stage	Necrosis advance
0	Without clinical evidence of necrotic bone but with the presence of nonspecific clinical symptoms and radiographic changes or symptoms.
1	Necrotic bone exposure without symptoms of infection
2	Necrotic bone exposure, accompanied by infection, pain, erythema with or without purulent exudate in the region of the exposed bone
3	Necrotic bone exposure with pain, infection, and one or more of the following aspects: Necrotic bone exposure causing pathologic fractures, extraoral fistula, oral sinus fistula, or osteolysis extending to the edge of the mandible or maxillary sinus.

The pathogenesis is multifactorial and implies a synergistic effect between local infection/trauma and decreased bone replacement after exposure to these agents. For this

reason, the objective of this literature review is to establish the drugs that have a greater probability of developing osteonecrosis of the jaw, the route of administration, dose and treatment time that carry a greater risk, and to establish adequate prevention strategies in order to provide new knowledge for the management of patients who are at risk or are developing medication-related osteonecrosis of the jaw.

2. Materials and methods

Inclusion criteria:

- Articles with a publication range 2018-2022.
- Full text availability.
- Articles available on databases in English, Portuguese and Spanish.
- Articles focused mainly on osteonecrosis of the jaws.

Exclusion criteria

- Case reports, books, magazines and documents
- Articles based on therapeutic options.
- Articles focused on osteoporosis.
- Duplicate articles.

Literature research

This literature review is based on the analysis of the existing bibliography of the last 5 years. The databases used for the research were PubMed, ScienceDirect and Springer Link with the use of terms derived from previous reading of scientific articles, because the different search strategies were: OSTEONECROSIS IN DENTISTRY, OSTEONECROSIS OF THE JAWS AND DRUG RELATED OSTEONECROSIS OF THE JAWS (Table 2).

Table 2. Search strategies

First search strategy: <i>Osteonecrosis in dentistry</i>	Second search strategy: Osteonecrosis of the jaws	Third search strategy: Drug-related osteonecrosis of the jaws
PubMed: 2147	PubMed: 4475	PubMed: 1196
ScienceDirect: 2180	ScienceDirect: 2523	ScienceDirect: 1297
SpringerLink: 1487	SpringerLink: 4725	SpringerLink: 635

3. Results

Data collection

There were 7 815 articles obtained from PubMed, 6 000 from ScienceDirect, and 6 847 from SpringerLink. After applying the filter “5 last-years”, 2630 articles remained in PubMed, 1313 articles in ScienceDirect, and 3608 in Springer Link. At the same time, different filters were applied such as: reviews, systematic reviews, meta-analyses, randomized controlled clinical trials, full text availability, and articles written in English, Spanish or Portuguese, from which 592, 180 and 200 articles were obtained respectively. When reading the titles, abstracts, applying inclusion, exclusion and duplicate articles criteria, 51 articles were selected for the literature review. Figure 1 illustrates the article selection diagram and results in Table 3.

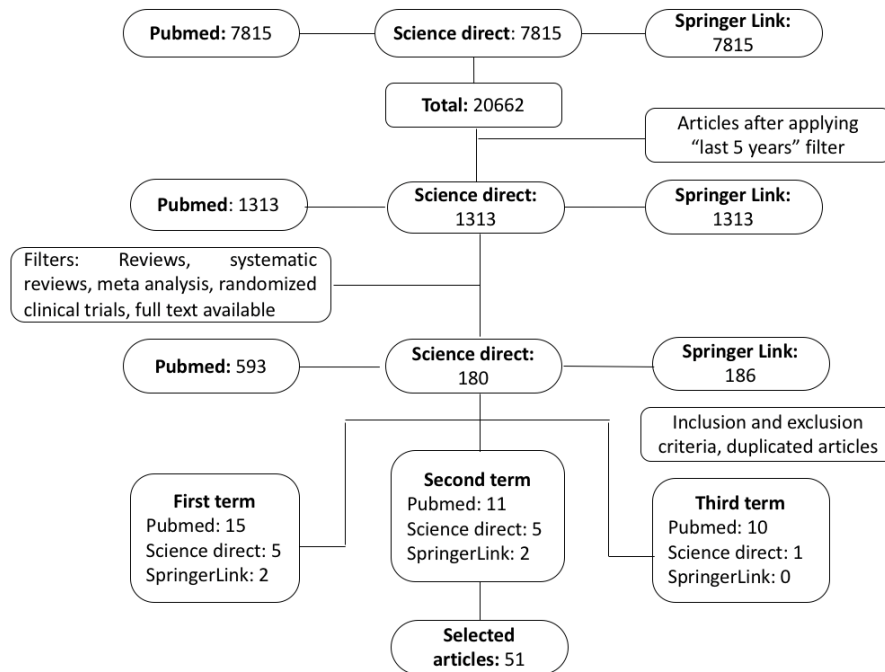


Figure 1. Literature Search Flow Chart

Table 3 Summary of the studies selected for literature review

Author	Article title	Year	Principal results
Ourania Morten, Rui Mendes, Carla Ripamonti, Sally Hope, Lawrence Drudge-Coates, Daniela Niepel, Tim Wyngaert	Medication-related osteonecrosis of the jaw: definition and best practice for prevention, diagnosis, and treatment.	2018	MRONJ is a rare adverse event associated with high cumulative doses of bisphosphonates or denosumab, prophylactic dental treatment decreases the risk of developing it.
Paweł Nieckula, Anna Stempniewicz, Monika Tubaja	Prophylaxis of osteonecrosis in the case of patients treated with bisphosphonates: A review paper	2018	Discontinuation of bisphosphonate therapy before dental procedures does not decrease the risk of osteonecrosis but should be considered as well as antibiotic prophylaxis.
Kün-Darbois, F. Fauvel	Medication-related osteonecrosis and osteoradionecrosis of the jaws:	2020	A tooth extraction is often found to be a trigger for MRONJ.

	Update and current management		
Cesar Augusto Migliorati	Oral Complications in Cancer Patients–Medication-Related Osteonecrosis of the Jaw (MRONJ).	2022	The exact mechanism leading to MRONJ formation is not yet known, it is a multifactorial process.
Kununya Pimolbutr, Stephen Porter , Stefano Fedele	Osteonecrosis of the Jaw Associated with Antiangiogenics in Antiresorptive-Naïve Patient: A Literature Review	2018	The mean duration of intravenous and oral antiangiogenics was 6.5 and 16.72 months, respectively, and the most frequent risk factor was dental extraction.
Roberto Sacco, Julian Woolley, Julian Yates, Monica Diuana Calasans-Maia, Oladapo Akintola, and Vinod Patel	The role of antiresorptive drugs and medication-related osteonecrosis of the jaw in nononcologic immunosuppressed patients: A systematic review	2021	The most common trigger for MRONJ was tooth extraction and with a high frequency of postoperative complications after treatment.
Hitesh Bansal	Medication-related osteonecrosis of the jaw: An update	2022	MRONJ is a relatively rare complication of antiresorptive and antiangiogenic medication, its prevention is key to its management.
H Kagami	Issues with the surgical treatment of antiresorptive agent related osteonecrosis of the jaws	2018	It is essential to develop less invasive therapies to prevent MRONJ progression and maintain patient's quality of life and alleviate symptoms.
George Bullock , Cheryl A. Miller , Alasdair	A Review into the Effects of Pamidronic Acid and	2022	BPs reduce cell viability, reduce proliferation, and increase apoptosis in

McKechnie ,Vanessa Hearnden	Zoledronic Acid on the Oral Mucosa in Medication-Related.		oral keratinocytes and fibroblasts, thus leading to reduced wound healing.
Akanksha Srivastava, María E. Cabanillas, Graciela M. Nogueras González, Aung Naing, Jeffrey Myers, Yimin Geng, Yisheng Li, Alexander Ganó, Mark Chambers	Prevalence of medication related osteonecrosis of the jaw in patients treated with sequential antiresorptive drugs: systematic review and meta- analysis	2020	There was a higher prevalence of MRONJ associated with sequential antiresorptive therapy for administration of pamidronate-zoledronate and denosumab bisphosphonate compared with single antiresorptive therapy.
J. Chang, A. E. Hakam, L. K. McCauley	Current Understanding of the Pathophysiology of Osteonecrosis of the Jaw	2018	The definitive pathophysiology is still unclear.
Minju Song	Dental care for patients taking antiresorptive drugs: A literature review	2019	MRONJ is rare but untreatable; therefore, physicians and dentists should be aware of the importance of preventing the development of ONJ.
K McGowan, T McGowan, S Ivanovski	Risk factors for medication- related osteonecrosis of the jaws: A systematic review	2017	MRONJ has been reported to occur in multiple myeloma, breast cancer, prostate cancer, and osteoporosis.
Ali Aboalela, Fathima Farook, Amerah Alqahtani, Mandlin Almousa, Rehab Alanazi, Duaa Almohammadi.	The Effect of Antiresorptive Drug Holidays on Medication- Related Osteonecrosis of the Jaw: A Systematic Review and Meta-Analysis	2022	Withholding antiresorptive therapy for a period does not minimize the risk of MRONJ.
António Marques, Carlos Polis-Yanes, Maria Seminario-Amez,Enric Jané-Salas,Jose López- López	MRONJ associated with implant and regenerative treatments: Systematic review.	2019	The risk of developing osteonecrosis associated with the regeneration/placement of implants in patients with benign bone diseases is low if the duration of treatment with BP

			is greater than 3 years and with administration of systemic corticosteroids.
Camila Foncea, Kristine Von, Cristian Teuber, Hernan Ramírez, Ignacio Goñi, Cesar Sánchez, Ignacio N. Retamal, Alex Vargas.	Drug-associated osteonecrosis of the jaw: Literature review and proposal for prevention and management	2020	The most effective way to prevent MRONJ is thorough dental, clinical, and imaging evaluation before starting therapy.
Mustafa Mian Subhashaan Sreedharan, Ricky Kumar.	Osteonecrosis of the jaws associated with protein kinase inhibitors: a systematic review	2020	The evidence related to MRONJ associated with protein kinase inhibitors is of low quality. There are many different clinical features of MRONJ associated with antiresorptive therapy.
Madhumati Singh, Giriraj Sandeep Gonegandla.	Bisphosphonate-Induced Osteonecrosis of the Jaws (BIONJ)	2019	Currently, there is no way to predict which people taking bisphosphonates are at higher risk of developing MRONJ.
Álvaro Limones, Luis Miguel Sáez-Alcaide, Pedro Molinero-Mourelle.	MRONJ in cancer patients treated with denosumab VS. zoledronic acid: A systematic review and meta-analysis	2020	The use of denosumab is associated with a significantly increased risk of developing MRONJ compared with zoledronic acid.
Mampeï Kawahara, Shinichiro Kuroshima, Takashi Sawase	Clinical considerations for medication-related osteonecrosis of the jaw: a comprehensive literature review	2021	Dentists should perform appropriate dental treatment to prevent MRONJ in patients before or when receiving medications that can induce MRONJ.
Aya Alsalih, Annica Dam, Anna Truedsson	Medication-Related Osteonecrosis of the Jaws	2021	Current findings show negative effects after ZA administration, leading to prolonged wound healing, chronic

	Initiated by Zoledronic Acid and Potential Pathophysiology		inflammation, and impaired bone remodeling.
Benjamin Palla, Egon Burian, Andrew Deek, John Anderson, Nicholas Callahan, Eric R. Carlos.	Comparing the Surgical Response of Bisphosphonate-Related Versus Denosumab-Related Osteonecrosis of the Jaws	2020	The surgical success rate for secondary MRONJ to denosumab was 80.0%, similar to that reported for bisphosphonates of 85 to 95%.
Asier Eguía, Leticia Bagan, and Francisco Cardona	Review and update on drugs related to the development of osteonecrosis of the jaw	2019	To prevent new cases of MRONJ, it is essential that all dentists are trained on etiopathogenic aspects.
Lina He, Xiangyu Sun, Yumei Niu.	Pathogenesis and multidisciplinary management of medication-related osteonecrosis of the jaw	2020	BP accumulation in the jaw can be competitively inhibited, this may be an effective method to prevent osteonecrosis of the jaw in the future.
Hikomitsu Kishimoto, Kazuma Noguchi, Kazuki Takaoka	Novel insight into the management of bisphosphonate-related osteonecrosis of the jaw (BRONJ)	2019	The presence of exposed bone in patients treated with BP does not necessarily cause BRONJ.
Kun-Jung Hsu, Szu-Yu Hsiao, Chun-Ming Chen.	Investigation of the Effectiveness of Surgical Treatment on Maxillary MRONJ: A Literature Review	2021	To prevent and control MRONJ, all elderly patients were suggested to maintain a proper oral hygiene routine and have a periodic dental examination.
S Bernardi, M Di Girolamo, S Necozone, M A Continenza, T Cutilli	Antiresorptive drug-related osteonecrosis of the jaws, literature review and 5 years of experience	2018	A surgically conservative strategy appears to be the best way to ensure a good life quality for patients adversely affected by this condition.
Olga Fede, Vera Panzarella, Rodolfo Mauceri, Vittorio Fusco, Alberto Bedogni, Lorenzo	The Dental Management of Patients at Risk of Medication-Related Osteonecrosis of the	2018	A multidisciplinary approach should be adopted among physicians involved in treating patients at risk of MRONJ and increasing the patient's life quality.

Muzio, Sipmo Board, Giuseppina Campisi.	Jaw: New Paradigm of Primary Prevention		
Raiza Querrer , Nathália Ferrare, Nilce Melo , Cristine Miron, Paula Diniz, Carla Moreira, Gabriel Borges , André Ferreira, Paulo Tadeu.	Differences between bisphosphonate-related and denosumab-related osteonecrosis of the jaws: a systematic review	2022	BP-related ONJ and AMDb-related ONJ manifest imaging features that are significantly more frequent in one condition than in the other.
Camila Foncea, Kristine Bischoffshausen, Cristián Teuber , Hernán Ramírez , Ignacio Goñi , Cesar Sánchez , Ignacio N Retamal , Alex Vargas	Osteonecrosis of the jaws	2020	The most effective way to prevent MRONJ is complete dental, clinical, and imaging evaluation before starting therapy.
Weidong Zhang, Ling Gao, Wenhao Ren, Shaoming Li, Jingjing Zheng, Shasha Li, Chunmiao Jiang, Shuying Yang, Keqian Zh	The Role of the Immune Response in the Development of Medication-Related Osteonecrosis of the Jaw	2021	These results suggested that impaired immunity plays an important role in the development of MRONJ.
Sven Otto, Suad Aljohani, Riham Fliefel, Sara Ecke, Oliver Ristow, Egon Burian, Matthias Troeltzsch, Christoph Pautke, Michael Ehrenfeld	Infection as an Important Factor in Medication-Related Osteonecrosis of the Jaw (MRONJ)	2021	They conclude that local infection plays a key role in the pathogenesis of MRONJ.
Aloizio Premoli Maciel, Reyna Aguilar Quispe , Lázara Joyce Oliveira Martins , Rogério Jardim Caldas , Paulo Sérgio da Silva Santos	Clinical profile of individuals with bisphosphonate-related osteonecrosis of the jaw: an integrative review	2020	BRONJ had a higher prevalence in women and the mandible was the most affected region with a moderate stage of BRONJ.

<p>Akanksha Srivastava , Graciela M Nogueras Gonzalez, Yimin Geng, Alexander M Won, Jeffrey Myers, Yisheng Li, Mark S Chambers</p>	<p>Medication-Related Osteonecrosis of the Jaw in Patients Treated Concurrently with Antiresorptive and Antiangiogenic Agents: Systematic Review and Meta- Analysis</p>	<p>2021</p>	<p>High-quality representative studies with larger sample sizes are needed for an accurate estimate of the relative risk of MRONJ.</p>
<p>Akanksha Srivastava, Graciela M Nogueras Gonzalez, Yimin Geng, Alexander M Won, Maria E Cabanillas, Aung Naing, Jeffrey N Myers, Yisheng Li, Mark S Chambers</p>	<p>Prevalence of medication related osteonecrosis of the jaw in patients treated with sequential antiresorptive drugs: systematic review and meta- analysis</p>	<p>2021</p>	<p>Higher prevalence of MRONJ associated with sequential ARD therapy for pamidronate-zoledronate and bisphosphonate-denosumab administration compared with single ARD therapy.</p>
<p>Masaya Akashi, Junya Kusumoto, Daisuke Takeda, Takashi Shigeta, Takumi Hasegawa, Takahide Komori</p>	<p>A literature review of perioperative antibiotic administration in surgery for medication-related osteonecrosis of the jaw</p>	<p>2018</p>	<p>Oral and maxillofacial surgeons mostly prefer penicillin-based antibiotics plus β-lactamase inhibitor or metronidazole for MRONJ surgery.</p>
<p>Raed Al Rowis, Abdulmalik Aldawood, Mohammed AlOtaibi, Essam Alnasser, Ibrahim AlSaif, Abdullah Aljaber, Zuhair Natto.</p>	<p>Medication-Related Osteonecrosis of the Jaw (MRONJ): A Review of Pathophysiology, Risk Factors, Preventive Measures and Treatment Strategies</p>	<p>2022</p>	<p>A collaborative approach involving dentists, physicians, and pharmacists is considered essential to prevent the development of MRONJ.</p>
<p>Aristilia Tahara, Vitor Hugo Ferreira, Rafael Mobile, Thais Brandao, Laurindo Sassi, Amanda Zarpellon, Paulo Braz- Silva, Juliana Schussel.</p>	<p>Risk factors for medication- related osteonecrosis of the jaw and salivary IL-6 IN cancer patients-</p>	<p>2022</p>	<p>There was no association between salivary IL-6 levels and MRONJ stages.</p>

<p>Nobuyuki Kaibuchi, Keika Hoshi, Ayame Yamazaki, Noriko Miyamoto-Sangu, Yuichi Akagi, Toshihiro Okamoto.</p>	<p>The progress of medication-related osteonecrosis of the jaw with conservative initial treatment: A 12-year retrospective study of 129 patients.</p>	<p>2021</p>	<p>The results showed that the cure rate did not decrease in patients with MRONJ.</p>
<p>Guang Yang, Sonal Singh, Yiqing Chen, Issam Hamadeh, Taimour Langaee, Caitrin McDonough, Shannon Holliday, Jatinder Lamba, Jan S.Moreb, JosephKatz, YanGong</p>	<p>Pharmacogenomics of osteonecrosis of the jaw</p>	<p>2019</p>	<p>Researchers believe that genetic factors play an important role in the development of MRONJ.</p>
<p>Estee L.George Yi-LingLin Marnie M.Saunders^a</p>	<p>Bisphosphonate-related osteonecrosis of the jaw: a mechanobiology perspective.</p>	<p>2018</p>	<p>Multiple factors, including blood pressure, load, and inflammation, act on multiple cell types to cause a defect in bone remodeling.</p>
<p>Saad Hajeri, Yasir Alturkistany</p>	<p>Medication-related osteonecrosis of the jaw after dental clearance: Prevalence in an oncology cent</p>	<p>2022</p>	<p>The prevalence of MRONJ in this study was within the average range reported in the literature, which is higher with the intravenous administration.</p>
<p>Devie Falinda Nicholas Malden</p>	<p>Case series: Osteonecrosis of the jaw related to denosumab preceded by bisphosphonates</p>	<p>2022</p>	<p>The potentially cumulative effect of BP and DSB on the development of MRONJ with tooth extraction is the main trigger.</p>

	in cancer and osteoporotic patients.		
Susan Diaz, Luis Naval-Gíaz, Mario Munoz-Guerra, Jesús Sastre-Pérez, Francisco Rodríguez y José Gil-Diez	Management of osteonecrosis of the jaw associated with the use of medications by virtue of its clinical stage: Analysis of 19 cases.	2018	A dental check-up is necessary before the administration of antiresorptive drugs to reduce the risk of the appearance of OMAM.
Lieselotte De Bruyn, Ruxandra Coropciuc, Wim Coucke, Constantinus Politis	Microbial population changes in patients with medication-related osteonecrosis of the jaw treated with systemic antibiotics	2018	Our findings suggest that the total bacterial level in MRONJ patients is higher even when treated with systemic antibiotics.
Coline Daron, Christophe Deschaumes, Martin Soubrier, Sylvain Mathieu.	Viewpoints of dentists on the use of bisphosphonates in rheumatology patients	2018	The guidelines also reported that annual IV administration of BP is weakly associated with the onset of ONJ.
Tormod B. Krüger, Bente B. Herlofson, Aina M. Lian, Unni Syversen, Janne E. Reseland	Alendronate and omeprazole in combination reduce angiogenic and growth signals from osteoblasts	2021	The combination of alendronate and omeprazole appeared to exaggerate the negative effects of each drug on human gingival osteoblasts and fibroblasts.
Seung Hun Lee, Choi tan jovent†, Min-Su Bae y Tae-Geon Kwon	Characteristics of patients with osteonecrosis of the jaw with oral versus intravenous bisphosphonate treatment	2021	IV administration of BP causes a severe inhibition of bone remodeling and could result in a higher degree of inflammation.

<p>P.J.Voss,D.Steybe, P.Poxleitner,R.Schmelzeisen, C. Munzenmayer, H. Fuellgraf, A. Stricker & W. Semper-Hogg</p>	<p>Osteonecrosis of the jaw in patients transitioning from bisphosphonates to denosumab treatment for osteoporosis</p>	<p>2018</p>	<p>They suggested that it was not necessary to stop oral BPs before dental procedures.</p>
<p>Kelly McGowan, Robert S. Ware, Caroline Acton, Saso Ivanovski & Newell W. Johnson</p>	<p>Both non-surgical dental treatment and extractions increase the risk of medication-related osteonecrosis of the jaw: case-control study</p>	<p>2019</p>	<p>Preventive dental care should be seen as an important factor in ensuring patients to take their antirheumatic medications safely.</p>
<p>Mampeï Kawahara, Shinichiro Kuroshima & Takashi Sawase</p>	<p>Clinical considerations for medication-related osteonecrosis of the jaw: a comprehensive literature review</p>	<p>2021</p>	<p>Before initiating potent antiresorptive therapy, a good oral status should be provided by a comprehensive dental evaluation.</p>

1. Discussion

The risk of MRONJ varies from low to high cumulative dose, duration of treatment, and frequency of administration of antiresorptive agents. Therefore, according to several studies, cancer patients who receive high doses of antiresorptive drugs have a greater risk of suffering from it. Patients receiving BP or Denosumab therapy for the treatment of bone metastases and multiple myeloma receive monthly doses of BP intravenously and Denosumab subcutaneously. While patients with osteoporosis or other disease such as Paget's require antiresorptive therapy at lower doses (zoledronic acid 5mg IV once a year and alendronic acid 10mg orally once a day) (Denosumab 60mg every 6 months, zoledronic acid 5 mg every 1 to 5 years) (17) (2) (40). In fact, Eguía A. et al shown that the risk is low for those patients who take oral bisphosphonates or denosumab for those with osteoporosis and who do not suffer from other pathologies. However, this risk increases considerably after the fourth year of treatment and is much higher in those patients who receive intravenous administration of bisphosphonates (23).

According to Granate et al, the majority of patients treated for osteoporosis receive intravenous or oral BP. The average duration of this treatment was 38 months in patients

receiving intravenous therapy and approximately 50 months in patients receiving oral BP administration, demonstrating that the majority of patients who developed MRONJ are associated with oral alendronate use (15) (47). However, the risk of osteonecrosis due to intravenous therapy with bisphosphonates must be evaluated since some authors mention that the BPs administered by this route have a high bioavailability and take more than 10 years to be metabolized and simultaneously eliminated in the bone tissue (16) (46).

On the other hand, Díaz S et al. mention that the risk of developing MRONJ by oral therapy is lower than its intravenous or subcutaneous administration in the case of denosumab, as evidenced in the results of this review in which 89% of patients were administered with this medication intravenously. Zoledronic acid (intravenous) is the drug most frequently associated with MRONJ, followed by denosumab (subcutaneous) and alendronate (oral). Furthermore, this drug causes a delay in the elimination of the cartilage matrix, which negatively affects bone development (17) (44) (28).

Despite the above, Rowis R. et al, have shown that the administration of denosumab will lead to a higher probability of developing MRONJ compared to zoledronic acid (37).

McGowan K et al, Premoli A et al, Kaibuchia N et al, Lee S, affirm that the location with the greatest tendency to develop MRONJ is the mandible in the posterior sector, specifically in the molar area, which could be attributed to the decreased vascularity of the mandible (13) (33) (44) (48). However, Falinda et al, determined that the region with the greatest involvement of MRONJ was the maxilla, contrasting with the information expressed in previous studies. Such affirmations are supported by the following information: 4 of the 8 cases analyzed were associated with dental surgical procedures exclusively in the maxilla, from this it is argued that the literature to reach this conclusion is still scarce, however all the procedures that involving manipulation of bone tissue, must be performed accurately, quickly, and atraumatically (43) (33).

Regarding gender, several authors established that women are the most affected with MRONJ, since it may be related to the administration of BP after menopause and with the high incidence of breast cancer and osteoporosis (13) (33).

According to the studies by McGOWAN et al, in the dental field, the procedure with the highest risk of developing MRONJ is extraction. For this reason, it is considered to suspend the antiresorptive drug if the extraction of a tooth is unavoidable (13) (15) (19).

Most authors agree that the risk is closely related to the patient's condition as it depends on the primary disease, duration and frequency of treatment with antiresorptive agents, however,

the suspension of these drugs at high doses remains uncertain in term of effectiveness in reducing the risk of MRONJ since Nieckula P et al, verify that the interruption of treatment with bisphosphonates for 3 months has little impact since they remain incorporated into the bone in a high percentage for many years after therapy, since it is estimated that alendronate can remain in the body for 10 years, even after a single dose. However, antiresorptive and antiangiogenic therapy should not be started before the mucosa has healed because it can recover if the effect of these drugs is reduced (2) (25).

With respect to risk factors, Zheng J et al and Otto S et al mention that part of the success of prevention is a correct anamnesis, since patients who are going to receive medications associated with the development of osteonecrosis should not present oral infectious processes and their oral health must be optimal. Evidence shows that dental care prior to starting treatment with bisphosphonates prevents the development of MRONJ (31) (32); information corroborated by Srivastava A et al, who emphasize that the treatment of dental caries, periodontal disease, and extraction of teeth infected or at risk of developing infection must be carried out at least 4 weeks before therapy with antiangiogenic and antiresorptive drugs (24) (34).

During treatment, invasive procedures should be avoided in high-risk patients, unless there are infectious processes that cannot be treated with conservative therapies. Extractions can be performed in patients with a low risk of developing osteonecrosis of the jaw in the primary care setting (17).

According to Galitis O et al, the risk of developing MRONJ can be reduced by antibiotic prophylaxis; the selection of the drug depends on individual factors of each patient (1). On the other hand, Nieckula P et al, do not recommend prior prophylactic therapy in all patients, they affirm that antibiotic prophylaxis should only be applied to high-risk patients such as systemic and cardiovascular diseases (2).

However, in recent years, various updates on the MRNOJ have determined that there is no effective prevention protocol, therefore, it is necessary to implement more reliable evidence to reach a consensus (44) (45).

2. Conclusion

Medication-related osteonecrosis of the jaw (MRONJ) is a rare but potentially serious adverse event that is associated with the prolonged use of antiresorptive and antiangiogenic agents, this is the reason why we conclude that dental professionals should be aware of the risk factors

associated with MRONJ development at the time of performing any dental procedure. It has not been possible to accurately determine the route of administration with the highest risk, due to the heterogeneity of evidence and dependence on the individual characteristics of each patient. It is essential to emphasize the importance of communication between the treating physician and the dentist to prevent these events, highlighting the preventive scope prior to the start of treatment with bisphosphonates, antiresorptive, and antiangiogenics.

3. Compliance with ethical standards

Acknowledgments

We would like to thank Dr. Martin Pesantez for his guidance and patience throughout the process. His experience and dedication were fundamental for the development of this work.

Disclosure of conflict of interest

The authors declared that they had no conflicts of interest with respect to the research, authorship and/or publication of this article.

Referencias

1. Nicolatou-Galitis O, Schiødt M, Mendes RA, Ripamonti C, Hope S, Drudge-Coates L, et al. Medication-related osteonecrosis of the jaw: Definition and best practice for prevention, diagnosis, and treatment. *Oral Surgery, Oral Medicine, Oral Pathology and Oral Radiology*. 2019;127(2):117–35.
2. Stempniewicz A, Tubaja M, Paweł N. Prophylaxis of osteonecrosis in the case of patients treated with bisphosphonates: A review paper. *Dental and Medical Problems*. 2018;55(4):425–9.
3. Kün-Darbois J-D, Fauvel F. Medication-related osteonecrosis and osteoradionecrosis of the jaws: Update and current management. *Morphologie*. 2021;105(349):170–87.
4. Migliorati CA. Oral complications in cancer patients—medication-related osteonecrosis of the jaw (MRONJ). *Frontiers in Oral Health*. 2022;3.
5. Pimolbutr K, Porter S, Fedele S. Osteonecrosis of the jaw associated with Antiangiogenics in antiresorptive-naïve patient: A comprehensive review of the literature. *BioMed Research International*. 2018; 2018:1–14.
6. Sacco R, Woolley J, Yates J, Calasans-Maia MD, Akintola O, Patel V. The role of antiresorptive drugs and medication-related osteonecrosis of the jaw in nononcologic immunosuppressed patients: A systematic review. *Journal of Research in Medical Sciences*. 2021;26(1):23.
7. Bansal H. Medication-related osteonecrosis of the jaw: An update. *National Journal of Maxillofacial Surgery*. 2022;13(1):5.
8. Kagami H, Inoue M, Kobayashi A, Taguchi A, Li X, Yoshizawa M. Issues with the surgical treatment of antiresorptive agent-related osteonecrosis of the jaws. *Oral Diseases*. 2018;24(1-2):52–6.
9. Bullock G, Miller CA, McKechnie A, Hearnden V. A review into the effects of pamidronic acid and zoledronic acid on the oral mucosa in medication-related osteonecrosis of the jaw. *Frontiers in Oral Health*. 2022;2.
10. Srivastava A, Noguera Gonzalez GM, Geng Y, Won AM, Cabanillas ME, Naing A, et al. Prevalence of medication related osteonecrosis of the jaw in patients treated with sequential antiresorptive drugs: Systematic Review and meta-analysis. *Supportive Care in Cancer*. 2020;29(5):2305–17.
11. Chang J, Hakam AE, McCauley LK. Current understanding of the pathophysiology of osteonecrosis of the jaw. *Current Osteoporosis Reports*. 2018;16(5):584–95.

12. Song M. Dental care for patients taking antiresorptive drugs: A literature review. *Restorative Dentistry & Endodontics*. 2019;44(4).
13. McGowan K, McGowan T, Ivanovski S. Risk factors for medication-related osteonecrosis of the JAWS: A systematic review. *Oral Diseases*. 2017;24(4):527–36.
14. Aboalela AA, Farook FF, Alqahtani AS, Almousa MA, Alanazi RT, Almohammadi DS. The effect of antiresorptive drug holidays on medication-related osteonecrosis of the jaw: A systematic review and meta-analysis. *Cureus*. 2022
15. Granate-Marques A, Polis-Yanes C, Seminario-Amez M, Jane-Salas E, Lopez-Lopez J. Medication-related osteonecrosis of the jaw associated with implant and regenerative treatments: Systematic review. *Medicina Oral Patología Oral y Cirugía Bucal*. 2019.
16. Foncea C, von Bischoffshausen K, Teuber C, Ramírez H, Goñi I, Sánchez C, et al. Osteonecrosis de los maxilares Asociada a medicamentos: Revisión de la literatura y propuesta para la prevención y manejo. *Revista médica de Chile*. 2020;148(7):983–91.
17. Mian M, Sreedharan S, Kumar R. Osteonecrosis of the jaws associated with protein kinase inhibitors: A systematic review. *Oral and Maxillofacial Surgery*. 2020;25(2):149–58.
18. Singh M, Gonedandla GS. Bisphosphonate-induced osteonecrosis of the jaws (BIONJ). *Journal of Maxillofacial and Oral Surgery*. 2019;19(2):162–7.
19. Limones A, Sáez-Alcaide LM, Díaz-Parreño SA, Helm A, Bornstein MM, Molinero-Mourelle P. Medication-related osteonecrosis of the jaws (MRONJ) in cancer patients treated with denosumab vs. Zoledronic acid: A systematic review and meta-analysis. *Medicina Oral Patología Oral y Cirugía Bucal*. 2020.
20. Kawahara M, Kuroshima S, Sawase T. Clinical considerations for medication-related osteonecrosis of the jaw: A comprehensive literature review. *International Journal of Implant Dentistry*. 2021;7(1).
21. Alsali A, Dam A, Lindberg P, Truedsson A. Medication-related osteonecrosis of the jaws initiated by Zoledronic acid and potential pathophysiology. *Dentistry Journal*. 2021;9(8):85.
22. Palla B, Burian E, Deek A, Scott C, Anderson J, Callahan N, et al. Comparing the surgical response of bisphosphonate-related versus denosumab-related osteonecrosis of the jaws. *Journal of Oral and Maxillofacial Surgery*. 2021;79(5):1045–52.

23. Eguia A, Bagán-Debón L, Cardona F. Review and update on drugs related to the development of osteonecrosis of the jaw. *Medicina Oral Patología Oral y Cirugía Bucal*. 2020.
24. He L, Sun X, Liu Z, Qiu Y, Niu Y. Pathogenesis and multidisciplinary management of medication-related osteonecrosis of the jaw. *International Journal of Oral Science*. 2020;12(1).
25. Kishimoto H, Noguchi K, Takaoka K. Novel insight into the management of bisphosphonate-related osteonecrosis of the jaw (BRONJ). *Japanese Dental Science Review*. 2019;55(1):95–102.
26. Hsu K-J, Hsiao S-Y, Chen P-H, Chen H-S, Chen C-M. Investigation of the effectiveness of surgical treatment on maxillary medication-related osteonecrosis of the jaw: A literature review. *Journal of Clinical Medicine*. 2021;10(19):4480.
27. Bernardi S, Di Girolamo M, Necozone S, Continenza MA, Cutilli T. Antiresorptive drug-related osteonecrosis of the jaws, literature review and 5 years of experience. *MUSCULOSKELETAL SURGERY*. 2018;103(1):47–53.
28. Di Fede O, Panzarella V, Mauceri R, Fusco V, Bedogni A, Lo Muzio L, et al. The dental management of patients at risk of medication-related osteonecrosis of the jaw: New paradigm of primary prevention. *BioMed Research International*. 2018;2018:1–10.
29. Querrer R, Ferrare N, Melo N, Stefani CM, dos Reis PE, Mesquita CR, et al. Differences between bisphosphonate-related and denosumab-related osteonecrosis of the jaws: A systematic review. *Supportive Care in Cancer*. 2020;29(6):2811–20.
30. Foncea C, von Bischoffshausen K, Teuber C, Ramírez H, Goñi I, Sánchez C, et al. Osteonecrosis de los maxilares Asociada a medicamentos: Revisión de la literatura y propuesta para la prevención y manejo. *Revista médica de Chile*. 2020;148(7):983–91.
31. Zhang W, Gao L, Ren W, Li S, Zheng J, Li S, et al. The role of the immune response in the development of medication-related osteonecrosis of the jaw. *Frontiers in Immunology*. 2021;12.
32. Otto S, Aljohani S, Fliefel R, Ecke S, Ristow O, Burian E, et al. Infection as an important factor in medication-related osteonecrosis of the jaw (MRONJ). *Medicina*. 2021;57(5):463.
33. Maciel AP, Quispe RA, Martins LJ, Caldas RJ, Santos PS. Clinical profile of individuals with bisphosphonate-related osteonecrosis of the jaw: An integrative review. *Sao Paulo Medical Journal*. 2020;138(4):326–35.
34. Srivastava A, Gonzalez GM, Geng Y, Won AM, Myers J, Li Y, et al. Medication-related osteonecrosis of the jaw in patients treated concurrently with antiresorptive and

- antiangiogenic agents: Systematic review and meta-analysis. *Journal of Immunotherapy and Precision Oncology*. 2021;4(4):196–207.
35. Srivastava A, Noguera Gonzalez GM, Geng Y, Won AM, Cabanillas ME, Naing A, et al. Prevalence of medication related osteonecrosis of the jaw in patients treated with sequential antiresorptive drugs: Systematic Review and meta-analysis. *Supportive Care in Cancer*. 2020;29(5):2305–17.
36. Akashi M, Kusumoto J, Takeda D, Shigeta T, Hasegawa T, Komori T. A literature review of perioperative antibiotic administration in surgery for medication-related osteonecrosis of the jaw. *Oral and Maxillofacial Surgery*. 2018;22(4):369–78.
37. AlRowis R, Aldawood A, AlOtaibi M, Alnasser E, AlSaif I, Aljaber A, et al. Medication-related osteonecrosis of the jaw (MRONJ): A review of pathophysiology, risk factors, preventive measures and treatment strategies. *The Saudi Dental Journal*. 2022;34(3):202–10.
38. Kemp AP, Ferreira VH, Mobile RZ, Brandão TB, Sassi LM, Zarpellon A, et al. Risk factors for medication-related osteonecrosis of the jaw and salivary IL-6 in cancer patients. *Brazilian Journal of Otorhinolaryngology*. 2022;88(5):683–90.
39. Kaibuchi N, Hoshi K, Yamazaki A, Miyamoto-Sangu N, Akagi Y, Okamoto T. The progress of medication-related osteonecrosis of the jaw with conservative initial treatment: A 12-year retrospective study of 129 patients. *Bone Reports*. 2021;14:101072.
40. Yang G, Singh S, Chen Y, Hamadeh IS, Langae T, McDonough CW, et al. Pharmacogenomics of osteonecrosis of the jaw. *Bone*. 2019;124:75–82.
41. George EL, Lin Y-L, Saunders MM. Bisphosphonate-related osteonecrosis of the jaw: A mechanobiology perspective. *Bone Reports*. 2018;8:104–9.
42. Hajeri S, Alturkistany Y. Medication-related osteonecrosis of the jaw after dental clearance: Prevalence in an oncology center. *The Saudi Dental Journal*. 2022;34(6):479–84.
43. Falinda D, Malden N. Case series: Osteonecrosis of the jaw related to denosumab preceded by bisphosphonates in cancer and osteoporotic patients. *Advances in Oral and Maxillofacial Surgery*. 2022;6:100258.
44. Diaz-Reverand SA, Naval-Gíaz L, Muñoz-Guerra MF, Sastre-Pérez J, Rodríguez-Campo FJ, Gil-Diez JL. Manejo de la Osteonecrosis Maxilar Asociada al Uso de medicamentos en virtud de Su Estadío Clínico: Análisis de 19 casos. *Revista Española de Cirugía Oral y Maxilofacial*. 2018;40(3):104–11.
45. De Bruyn L, Coropciuc R, Coucke W, Politis C. Microbial population changes in patients with medication-related osteonecrosis of the jaw treated with systemic

- antibiotics. *Oral Surgery, Oral Medicine, Oral Pathology and Oral Radiology*. 2018;125(3):268–75.
46. Daron C, Deschaumes C, Soubrier M, Mathieu S. Viewpoints of dentists on the use of bisphosphonates in rheumatology patients. *International Dental Journal*. 2018;68(4):279–86.
47. Krüger TB, Herlofson BB, Lian AM, Syversen U, Reseland JE. Alendronate and omeprazole in combination reduce angiogenic and growth signals from osteoblasts. *Bone Reports*. 2021;14:100750.
48. Lee S-H, Choi S-Y, Bae M-S, Kwon T-G. Characteristics of patients with osteonecrosis of the jaw with oral versus intravenous bisphosphonate treatment. *Maxillofacial Plastic and Reconstructive Surgery*. 2021;43(1).
49. Voss PJ, Steybe D, Poxleitner P, Schmelzeisen R, Munzenmayer C, Fuellgraf H, et al. Osteonecrosis of the jaw in patients transitioning from bisphosphonates to denosumab treatment for osteoporosis. *Odontology*. 2018;106(4):469–80.
50. McGowan K, Ware RS, Acton C, Ivanovski S, Johnson NW. Both non-surgical dental treatment and extractions increase the risk of medication-related osteonecrosis of the jaw: Case-control study. *Clinical Oral Investigations*. 2019;23(11):3967–75.
51. Kawahara M, Kuroshima S, Sawase T. Clinical considerations for medication-related osteonecrosis of the jaw: A comprehensive literature review. *International Journal of Implant Dentistry*. 2021;7(1).