

UCUENCA

Universidad de Cuenca

Facultad de Odontología

Carrera de Odontología

Técnicas de abordaje quirúrgico para extracción de mesiodens impactados o retenidos: revisión de la literatura

Trabajo de titulación previo a la obtención del título de Odontólogo


Autores:

Jonnathan Antonio Pasaco González

Yuliana del Cisne Luzuriaga Torres

Director:

Mario Esteban Calderón Calle

ORCID:  0000-0003-1320-2923

Cuenca, Ecuador

2023-10-12

Resumen

El mesiodens corresponde a una anomalía de número del desarrollo dental, que se forma entre los incisivos centrales superiores. Se diagnostica mediante examen radiográfico y la opción terapéutica precisa es la extracción. El objetivo de este estudio es revisar las diferentes técnicas quirúrgicas empleadas en la extracción de mesiodens intraóseos mediante una revisión bibliográfica. Metodología: La recopilación de información se realizó a través de la búsqueda y selección de artículos relacionados con técnicas quirúrgicas para la extracción de mesiodens intraóseo, en las bases de datos electrónicas PubMed, Google Académico y Journal of Dental Research. Los criterios de selección tomados en cuenta fueron: antigüedad no mayor a 5 años, palabras clave, estudios en humanos, mesiodens retenidos o incluidos. De un total de 113 artículos se escogieron 17 que están acorde con los criterios de esta investigación. Resultados y Conclusiones: El abordaje quirúrgico a mano libre tiene buenos resultados, pero el uso de guías quirúrgicas mejora la satisfacción del paciente, reduce el tiempo operatorio y la dificultad de la cirugía y facilita las osteotomías e incisiones más precisas, sin dañar tejidos de forma innecesaria lo que da como resultado una mejoría postoperatoria más satisfactoria.

Palabras clave: mesiodens, hiperdoncia, diente supernumerario anterior, incisivo retenido.



El contenido de esta obra corresponde al derecho de expresión de los autores y no compromete el pensamiento institucional de la Universidad de Cuenca ni desata su responsabilidad frente a terceros. Los autores asumen la responsabilidad por la propiedad intelectual y los derechos de autor.

Repositorio Institucional: <https://dspace.ucuenca.edu.ec/>

Abstract

The mesiodens corresponds to a number anomaly of dental development, which is formed between the upper central incisors. It is diagnosed by radiographic examination and the precise therapeutic option is extraction. The aim of this study is to review the different surgical techniques used in the extraction of intraosseous mesiodens by means of a review of the literature. Methodology: The collection of information was carried out through the search and selection of articles related to surgical techniques for the extraction of intraosseous mesiodens in the electronic databases PubMed, Google Scholar and Journal of Dental Research. The selection criteria taken into account were: age not older than 5 years, key words, human studies, impacted or retained mesiodens. From a total of 113 articles, 17 were chosen that are in accordance with the criteria of this research. Results and Conclusions: The free hand surgical approach has good results, but the use of surgical guides improves patient satisfaction, reduces operative time and difficulty of surgery and facilitates more precise osteotomies and incisions, without unnecessary tissue damage resulting in a more satisfactory postoperative improvement.

Keywords: mesiodens, hyperdontia, anterior supernumerary tooth, retained incisors.



The content of this work corresponds to the right of expression of the authors and does not compromise the institutional thinking of the University of Cuenca, nor does it release its responsibility before third parties. The authors assume responsibility for the intellectual property and copyrights.

Institutional Repository: <https://dspace.ucuenca.edu.ec/>

Índice de contenido

Introduction.....	7
Methodology.....	7
Discussion.....	18
Conclutions.....	20
References.....	21

Índice de figuras

Figura 1: Flow chart: Selection of articles.....	8
---	---

Índice de tablas

Tabla 1: Review of observational, literature review and experimental articles on the surgical approach to mesiodens extraction.....9

Introduction

Mesiodens corresponds to a number anomaly of dental development, which is formed between the upper central incisors (1). It is present in the deciduous and permanent dentition with an incidence between 0.2% to 0.8% (2) from 0.1% to 1.9% respectively (3). They represent 80% of all supernumerary teeth. Its incidence is 90% in the maxilla (2). According to sex it is more prevalent in males than in females with a ratio of 2 to 1 (1–3).

The etiology of mesiodens is unknown, but it is believed that it may be related to genetic factors, dental lamina hyperactivity, dental button dichotomy, cleft lip and palate (1,2,4). It is also related to syndromes such as cleidocranial dysplasia, Gardner syndrome, Fabry Anderson syndrome, Nance-Horan syndrome and Ellis-van Crevald síndrome (1,5).

Complications brought about by the presence of mesiodens are problems with normal eruption, dental malposition/clamping, midline diastema, root resorption, pulp necrosis, esthetic problems, periodontal disease, development of dentigerous cysts, ectopic eruption of central incisors (1,2,6). In most cases mesiodens are diagnosed by radiographic examination and the precise therapeutic option is its extraction (1), however, due to the high prevalence of this dental piece, there are several protocols or surgical guides to extract the piece based on its location and whether it is erupted or unerupted.

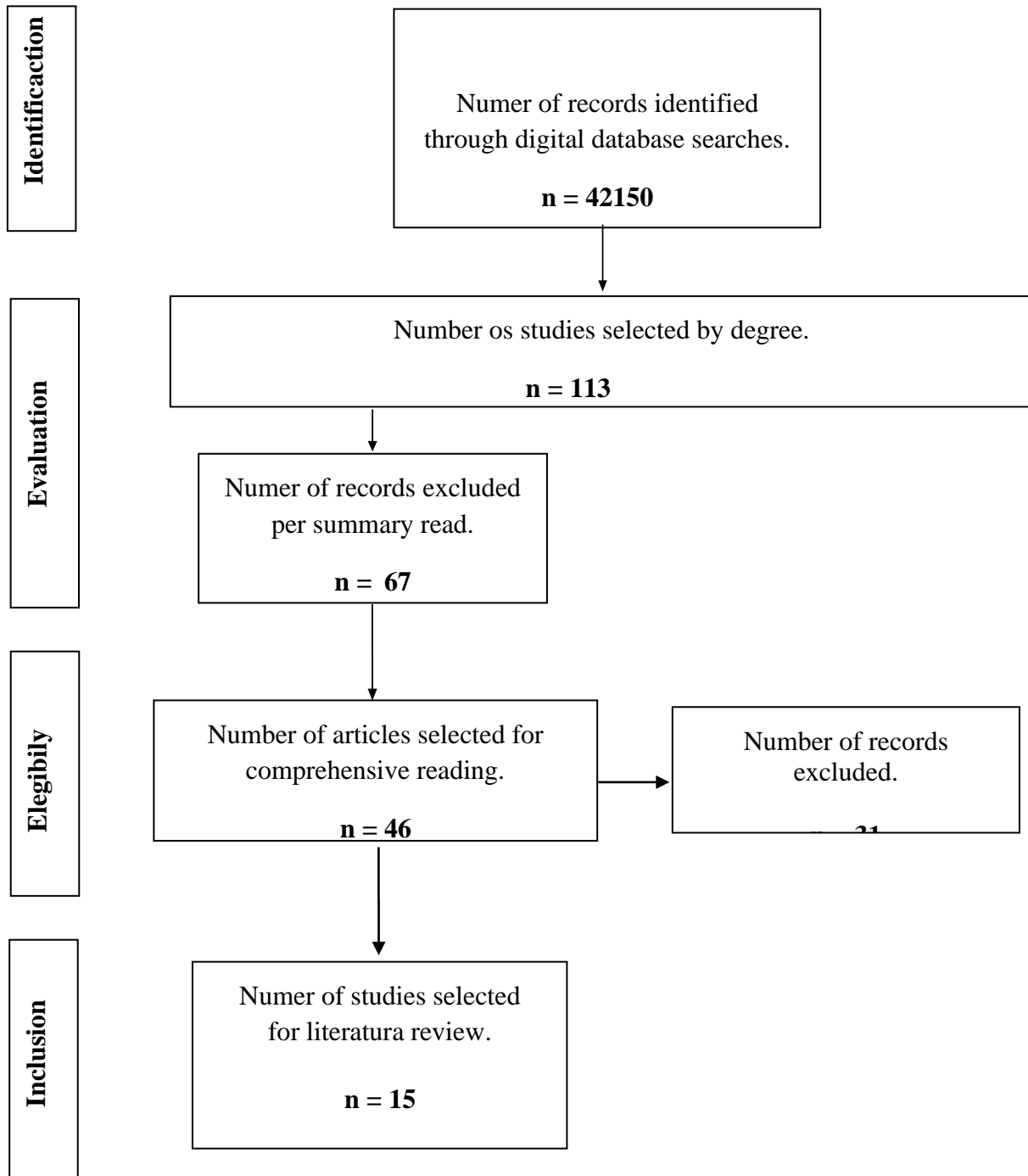
The objective of this study is to review the different surgical techniques used in the extraction of intraosseous mesiodens, as well as the benefits and complications of each by means of a literature review.

Methodology

This scientific article was developed using a descriptive research methodology. The collection of information was carried out through the search and selection of articles related to surgical techniques for the extraction of impacted or retained mesiodens in the electronic databases PubMed, Google Scholar and Journal of Dental Research. We worked with a qualitative approach and the research design is non-experimental cross-sectional. Keywords such as mesiodens, hyperdontia and anterior supernumerary tooth were used in three different languages: English, Spanish and Portuguese. In addition, a search interaction was developed with the help of the Boolean operator "AND", relating the keywords: mesiodens; hyperdontia; supernumerary teeth (supernumerary teeth SNT); surgical; interincisal and central incisors. The minimum requirement for the article to be eligible is that it must not be older than 5 years, and that it does not involve surgery on erupted supernumerary teeth or in another position. The total number of articles collected through the selection by titles was 113, of which 67 were

excluded due to abstract reading, being 46 the articles selected for complete review and of which 31 were excluded due to lack of relevant information for the research and repetition, leaving a total of 15 articles to be used in the review of the literature.

Figure 1. Flow chart. Selection of articles.



Source: Autors (2022).

Results

The following table shows the surgical techniques used for mesiodens extraction from different clinical cases. Not all authors correctly record the steps and detail the procedure. It is shown that the full-thickness palatal mucoperiosteal flap approach is the most used, since the mesiodens has a prevalence of being directed palatally (Table 1). Systematic articles show that the most common shape of the mesiodens is conical and uniradicular. The studies demonstrate patient satisfaction with the different treatment options.

Table 1: Review of observational, literature review and experimental articles on the surgical approach to mesiodens extraction.

Article title	Authors and year of publication	Magazine name	Sex and age	Shape and position	Description of the surgical technique used
Precise extraction of impacted supernumerary tooth in the maxillary anterior region with a digital guide plate A case	Fangyong y cols. (2022).	Medicine Journal	12 year old female.	Inverted and conoid-shaped towards palatal.	Disinfection of the operating region, local anesthesia with primacaine, incisions were made and the mucoperiosteal flap was lifted, bleeding was controlled and the surgical guide was placed. Osteotomy with calibrated round bur until exposing the tooth, with a fissure bur to section. The guide was removed and the tooth fragments were extracted. Hemostasis, saline irrigation, and flap suture were performed (7).

report					
A randomized controlled trial: evaluation of efficiency and safety of a novel surgical guide in the extraction of deeply impacted supernumerary teeth in the anterior maxilla	Jiefan y cols. (2022).	Annals of Translation al Medicine.	Group of 23 men with an age range of 9.4±3.8 5 and a group of 17 women with an age range of 9.52±4. 35. Divided into two groups.	From a group of 40 mesiodens: towards the palatal (36), towards the labial (3) and on the arch (1). With an inverted (26), vertical (5), inclined (8) and horizontal (1) direction.	Group 1: Installation of the guide, anesthesia, incision and lifting of the mucoperiosteal flap. Fixation of the second osteotomy guide was achieved with its T-slot. The already calibrated depth exposed the supernumerary teeth, the guide was withdrawn and extraction performed. Finally, it was washed with 0.9% saline solution and the flap was sutured with a 4-0 braid. Group 2: Incisions were made at the gingival margin and a trapezoidal flap. The other steps were the same as group 1 except for the use of the guide (8).
A conservative approach to a mesiodens removal via	Guião-Fernandes y cols. (2022).	Elsevier Ltd on behalf of British Association of Oral and Maxillofacial Surgeons.	13 years.	Angulation between 90-180.	Intravenous sedation with Midazolam. Local anesthesia was performed lateral to the labial frenulum with 4% articaine + epinephrine 1:1,000,000. With hemostatic forceps and a 15C blade, the

<p>frenectomy incision. A case report</p>					<p>frenulum was separated and the incision was widened vertically. A bilateral mucoperiosteal flap was raised and the edges of the flap were fixed with 5-0 nylon suture to separate it atraumatically. The osteotomy was made 15mm apical to the papilla. Once the tooth was exposed, it was avulsed with an apex elevator. 4 platelet-rich fibrin membranes were inserted into the alveolus and 2 covering the bone defect. Finally, the flap was closed with 6-0 nylon suture (9)</p>
<p>Fusion of Unerupted Mesiodentals with a Regular Maxillary Central Incisor: a Diagnostic and Therapeutic Challenge</p>	<p>Šarac y cols. (2021).</p>	<p>Croatian Stomatological Act</p>	<p>17 year old male.</p>	<p>Located towards the palatine with the shape of a maxillary canine and the second vertically conical in</p>	<p>Infiltrative local anesthesia with two 1/1,000,000 cartridges of articaine/epinephrine hydrochloride. Through a vertical incision with unilateral relief along the gingival margin to lift the palatal flap. The osteotomy with the KaVo INTRAsurg 300 turbine with 0.9% sodium chloride solution for cooling. An opening was made from the vestibular and with a Bein lever the</p>

					tooth was extracted exerting force from the vestibular so that it descends through the mucosal and bony opening released by the palatine, as an intraoperative finding a fusion of the second supernumerary tooth with the crown and cervical third of the root of tooth 21, was dislodged using a long tapered flat end diamond bur to allow complete removal. The surface was polished to give morphology. Finally, a submucosal periosteal graft was prepared in the interincisal papilla and sutured (10).
Supernumerary Teeth Management in the Anterior Maxilla: A Report of Two Cases	Alouany cols. (2021).	SAS Journal of Surgery.	Case 1: 11 years masculine.	It is located palatal and inclined to the left of the partially erupted central incisor.	Case 1: Intrasurgical incision and full-thickness flap lift. Bone tissue was removed under saline irrigation, extraction, and flap replacement by simple suture (11).
Surgical	Aham	Internationa	Case 1:	Case 1: Single	Case 1: Local anesthesia

<p>Management of Impacted Supernumerary Tooth: A Case Series</p>	<p>med y cols. (2021).</p>	<p>Journal of Clinical Pediatric Dentistry</p>	<p>10-year-old girl. Case 2: 9-year-old patient. Case 3: 8-year-old boy.</p>	<p>supernumerary in palatal position between 21 and 11, fused to 21. Case 2: SNT with a complete and uniradicular crown located palatally at 11, in a vertical position with the crown directed towards the occlusal plane. Case 3: 2 TNS, one erupted and one mesiodens retained inverted and in a palatal direction.</p>	<p>and full thickness mucoperiosteal flap lifting, the bone was removed selectively and in a circular fashion to expose the tooth. In this way, the odontosection was carried out since it was fused with the root of number 21; both were extracted and sutured. Case 2: Extraction of the TNS associated with 11 and surgical removal of 21 for correct post-endodontic reimplantation. Case 3: Simple extraction of the erupted TNS. For the mesiodens, a palatal flap was performed and selective removal of bone with drills, the mesiodens was exposed and extracted. Finally, the flaps were sutured and a periodontal plug was placed (12).</p>
<p>An Impacted Inverted Mesiodens and Its Surgical</p>	<p>Agarwal y cols. (2020).</p>	<p>International Journal of Pedodontic Rehabilitation</p>	<p>Female - 6 years.</p>	<p>Dilacerated root located in the buccal alveolar crest of the maxillary</p>	<p>Midazolam as a pre-anaesthetic. Propofol to intubate and anesthesia maintained with O2 and N2O. Vecunorio to relax muscles. Local infiltrative</p>

Intervention				cortex.	anesthesia with 2% lidocaine plus 1/1,000,000 epinephrine with a 30G needle. Incision on the midline of the alveolar crest and flap lifting, dislocation with levator rectus, curettage and saline irrigation. It was sutured with 3-0 and 4-0 silk thread and extubated (13).
Surgical Management of Unerupted Permanent Maxillary Central Incisors Due to Presence of Two Supernumerary Teeth	Alsweedy cols. (2020).	International Journal of Clinical Pediatric Dentistry	Male - 11 years	One in the form of a central incisor and another with multiple cusps and root forming with dens invaginatus.	Local anesthesia, mucoperiosteal flap, dislocation and avulsion. Control of hemostasis and replacement of the flap (14).
Application of a surgical guide in the	Xianghui cols. (2020).	Clinical Oral Investigations: Springer	60 patients in 3 groups of 20	Does not register	Group 1-2: General anesthesia, surgical guide placement using outer edge as incision line, fan flap preparation, guide

<p>extraction of impacted mesiodentes: a randomized controlled trial</p>			<p>with an age of 6-18 years</p>		<p>removal, mucoperiosteal flap raised. The locating guide is placed and a bur is passed through the hole perpendicular to the guide to expose the tooth. The guide was replaced by a surgical one to fragment the tooth, washed and sutured.</p> <p>Group 3: Incision in the gingival margin, with a trapezoidal flap and without the use of a guide. Using the hands-free technique to locate the SNTs, the rest of the steps were the same as for groups 1 and 2 (15).</p>
<p>Surgical management of mesiodens based on characteristics and complications of the condition: A systematic review</p>	<p>Rahadi and cols. (2020).</p>	<p>Journal of Stomatology.</p>	<p>6-10 years old.</p>	<p>Prevalence of conical crowns, to a lesser extent canine crown, tuberculate or round incisor, multilobed crowns were also recorded.</p> <p>Regarding the position was registered</p>	<p>When the mesiodens has fully erupted, it can be removed by simple extraction (immediate treatment), but an inverted mesiodens may require surgical removal (delayed treatment) to prevent damage to adjacent permanent teeth. The number of mesiodens (single or multiple) or the shape of the crown are usually not considered when determining the</p>

				vertical (55-72%), horizontal or inverted.	treatment method in these cases (16).
Tratamiento cirúrgico de dientes supranumerarios na região anterior da maxila em paciente pediátrico : estudo de caso	Nogueira y cols. (2020).	Revista Eletronica Acervo Saúde / Electronic Journal Collection Health.	Male patient, 8 years old.	A mesiodens in the midline of the upright conical shaped maxilla. 2 retained and impacted rounded supernumerary teeth.	Incision with a 15c scalpel in the upper part of the ridge, intrasulcularly and with relaxant in tooth 63, then total detachment was produced with the help of the syndesmotome until exposing the TNS. The three supernumerary elements were then dislocated with the aid of straight levers and extraction performed. Subsequently, the region was inspected and irrigated with 0.9% saline solution. The flap was readjusted and sutured with 4-0 silk thread (17).
Bilateral Mesiodens in a 11 Year Old Patient- A Case Report	Geethanjali y col. (2020).	Journal of Advanced Medical and Dental Sciences Research.	11 year old boy	Two vertically impacted 16mm conical SNT located towards the palatine of 11 and 21 respectively.	Nasopalatine nerve anesthesia and buccal infiltration were achieved and the sulcular incision in the palate extended from distal of 23 at the alveolar crest to the distal aspect of 13. The full thickness flap was raised, and bone was removed and removed. the

					two mesiodens. Finally, it was sutured with simple stitches (18).
Mesiodens and its Complication in Anterior Maxilla: A Case Report	Dixit y cols. (2019).	International Journal of Oral Care and Research	Does not specify gender - 12 years	Inverted towards palatal	Antibiotic therapy one day before. Local vestibular and palatal anesthesia in region 21-13. Incision and elevation of the mucoperiosteal flap, osteotomy with saline irrigation. Dislocation by periosteal elevator and avulsion. Curettage and flattening are performed with a bone file. Replacement of the flap and suture using 3-0 braided silk (19).
Mesiodens: Diagnóstico e intervenção cirúrgica. Relato de caso	Carros y col. (2018).		male 7 years	Conical shape, uniradicular, vestibulovergated.	Pre-anesthesia with Midazolam = 0.5 mg/kg 30 minutes before the surgical process. Extraoral antiseptics with povidone iodine and intraoral with 0.12% chlorhexidine. Infiltrative vestibular and palatal anesthesia towards mesial and distal with 3% prilocaine with 0.03 IU/ml felypressin. With a #15 scalpel blade to incise the vestibular interdental papillae and a flap was

					raised with a Molt #9 separator. Avulsion was performed with 150 forceps. Curettage and irrigation with saline solution and simple suture with absorbable vycril 4-0 thread (20).
Evaluation of Surgical Options for Supernumerary Teeth in the Anterior Maxilla	Maddaloni et al. (2018).	International Journal of Clinical Pediatric Dentistry	41 male and 28 female patients. Ages 6-19 years.	Conical shape prevalence in permanent dentition. Position: 41 vertical teeth, 9 mesially or distally inclined and 4 horizontal	Elevation of a full-thickness intrasulcular mucoperiosteal flap (vestibular, palatal, or both). When the SNT is not visible on flap elevation, a window is created in the bone wall for access. If necessary, odontosection was performed with an air rotor handpiece or the bicordia approach was chosen (21)

Source: Authors (2023).

Discussion

Mesiodens can develop in different positions within the arch, the most prevalent being the vertical position (55.2%), followed by the inverted position (37.6%) and finally the horizontal (7%), they are also unerupted in 62.9% of cases (13). The surgical approach is decided based on the location, size and position of the tooth, however, the surgical times are generally the same (22). When the surgical procedure is performed for the extraction of impacted or retained mesiodens there is a risk of developing iatrogenesis to the developing permanent teeth, for this reason it is necessary to perform an accurate clinical and imaging diagnosis of the location and position of the supernumerary tooth (13).

Cone beam computed tomography is an advanced radiographic technique to detect the presence of impacted mesiodens (13,23,24). In addition, it provides a greater amount of data to the surgeon and allows the development of new techniques as mentioned by Zhu, which performed the extraction of an impacted supernumerary tooth with the help of a surgical guide developed based on CBCT data reconstruction, the results showed that the surgery was less invasive, more precise and faster. The data obtained in the study demonstrate that cone beam computed tomography is the most widely used method in the diagnosis of mesiodens (7).

The study data reveal that the main reason for patient consultation is due to delayed tooth eruption and its most common cause is due to the presence of supernumerary teeth (14). Another problem is due to dental misalignment (7,19), or a mixture of both (23). Thus, surgical extraction of the mesiodens is indicated to solve late dental eruption, malocclusions, resorption of adjacent teeth, formation of dentigerous cysts, esthetic and functional problems. We have to consider the diversity of complications in each case, therefore, there is no standard protocol for the resolution of the problem, but the treatment should be individualized and personalized for each patient (23). Several studies that talk about achieving postoperative compliance such as those of Liu (8), have to do with a multidisciplinary management essential to obtain good results and few complications (12). In several cases, tooth eruption happens on its own after mesiodens extraction (13,14,23), but in others orthodontic traction is necessary (19,25,26). Then, to achieve the treatment goal, surgical extraction alone is not enough, as there must be a multiple approach with other areas to restore function and esthetics to patients.

According to Table 1, most surgical approaches are based on the free hand technique which consists of making an incision and lifting a full thickness mucoperiosteal flap. If the case requires it, the labial approach can be performed with apical flaps with release incisions (13). The bone is then worn down to expose the mesiodens, where it is decided according to the case, in complete or fragmentary exodontia. To finish with hemostasis, irrigation and suture of the flap. But this technique can have several drawbacks such as increased bone wear, affect adjacent tissues and prolonged post-surgical recovery. Current technologies such as 3D printing for the elaboration of the guides allow this type of surgery to be approached in a more efficient manner. Thus, the use of surgical guides avoids these complications by making mesiodens extractions minimally invasive and more precise (7). In addition, they reduce the risk and difficulty of osteotomy, significantly decrease the surgical time and its post-surgical complications (8). Also as pointed out by Liu (2022) the main drawback of the guides is that they cannot guide the incision, its angle

and depth of extracted bone tissue which could impair and increase the risk of the process(8). Therefore, the ideal approach should be simultaneous, obtain a good imaging exam, a guide that fits correctly and be instructed about the surgical techniques to obtain good results.

In the data collection, a considerable amount of information was obtained about the surgical procedure used for the extraction of mesiodens; however, little information was found on the postoperative results of the surgery; therefore, it is not possible to define which technique offers the best results for the extraction of a supernumerary tooth.

Conclusions

Clinical examination is not always sufficient to correctly diagnose the presence of mesiodens. Dentists should rely on imaging tests such as periapical radiographs, panoramic radiographs and cone beam computed tomography which provide detailed information about the position, orientation and relationship of mesiodens with neighboring structures. A determining factor in deciding the treatment plan is the position of the mesiodens and its proximity to the incisors. The free hand surgical approach has good results, but the use of surgical guides improves patient satisfaction, reduces operative time and surgical difficulty and facilitates more precise osteotomies and incisions, without unnecessary tissue damage resulting in a more satisfactory postoperative improvement.

Referencias

1. Hernández V, Alejandra M, Scougall-Vilchis ;, José R, Robles-Bermeo ;, Leticia N, et al. Mesiodens: Diagnóstico, aspectos clínicos, radiográficos y tratamiento. Revisión bibliográfica. 2018; Available from: <https://www.redalyc.org/articulo.oa?id=331367295003>
2. Figueroa L, Smith ;, Daza ;, Polanco ;, Andraca F. Abordaje Transoral para la Extracción de un Diente Supernumerario Intranasal. Presentación de un Caso y Revisión de la Literatura Transoral Approach for Intranasal Supernumerary Tooth Extraction. Case Report and Literature Review. Vol. 16, Int. J. Odontostomat. 2022.
3. Goksel S, Agirgol E, Karabas HC, Ozcan I. Evaluation of Prevalence and Positions of Mesiodens Using Cone-Beam Computed Tomography. J Oral Maxillofac Res. 2018 Dec 30;9(4).
4. Tetay-Salgado S, Arriola-Guillén LE, Ruíz-Mora GA, Castillo AA Del, Rodríguez-Cárdenas YA. Prevalence of impacted teeth and supernumerary teeth by radiographic evaluation in three Latin American countries: A crosssectional study. J Clin Exp Dent. 2021 Apr 1;13(4):e363–8.
5. Oliva Chumán J. Diente supernumerario mesiodens en posición transversal invertida. Reporte de caso. Cultura [Internet]. 2019 Dec 30;33:391–8. Available from: http://www.revistacultura.com.pe/revistas/RCU_33_dientesupernumerario.pdf
6. Torres L. Tratamiento de supernumerarios en zona anterosuperior. Presentación de un caso. Revista Mexicana de Ortodoncia. 2018 Jun 1;6(2):122–4.
7. Zhu F, Hou D, Zhou C, Chen Z, Cao Y, Ji L, et al. Precise extraction of impacted supernumerary tooth in the maxillary anterior region with a digital guide plate: A case report. Medicine (United States). 2022 May 20;101(20).
8. Liu J, Wang X, Shan P, Hu S, Liu D, Ma J, et al. A randomized controlled trial: evaluation of efficiency and safety of a novel surgical guide in the extraction of deeply impacted supernumerary teeth in the anterior maxilla. Ann Transl Med. 2022 Mar;10(6):292–292.
9. Guião-Fernandes D, Avelar K, Melo V, Caetano AC, Padovani L. A conservative approach to a mesiodens removal via frenectomy incision. A case report. Advances in Oral and Maxillofacial Surgery. 2022 Jan;5:100237.
10. Šarac Z, Zovko R, Cvitanovic S, Goršeta K, Glavina D. Fusion of unerupted mesiodens with a regular maxillary central incisor: A diagnostic and therapeutic challenge. Acta Stomatol Croat. 2021 Sep 1;55(3):325–31.
11. Alouani N, Messaoud NS Ben, Jlassi D, Retibi M, Bouzlama G, Youssef S Ben. Supernumerary Teeth Management in the Anterior Maxilla: A Report of Two Cases. SAS Journal of Surgery. 2021 Nov 13;7(11):666–9.

12. Ahammed H, Seema T, Deepak C, Ashish J. Surgical management of impacted supernumerary tooth: A case series. *Int J Clin Pediatr Dent*. 2021 Sep 1;14(5):726–9.
13. Agarwal N, Jabin Z, Kalita S. An impacted inverted mesiodens and its surgical intervention. *International Journal of Pedodontic Rehabilitation*. 2020 Jun 1;5(1):22–4.
14. Alsweed AA, Al-Sughier Z. Surgical management of unerupted permanent maxillary central incisors due to presence of two supernumerary teeth. *Int J Clin Pediatr Dent*. 2020 Jul 1;13(4):421–4.
15. Zheng X, Zhao J, Liu S, Wang Z, Jia B, Lin X. Application of a surgical guide in the extraction of impacted mesiodentes: a randomized controlled trial. Vol. 25, *Clinical Oral Investigations*. Springer Science and Business Media Deutschland GmbH; 2021. p. 2999–3006. *World Journal of Advanced Research and Reviews*, 2023, 18(03), 291–300 300
16. Rahadian B, Julia V, Sulistyani LD. Surgical management of mesiodens based on characteristics and complications of the condition: A systematic review. Vol. 73, *Journal of Stomatology*. Termedia Publishing House Ltd.; 2020. p. 261–9.
17. Nogueira JSE, Lima ACS, Rodrigues RFS, Nogueira PA, Fonseca RR de S, Cardoso ACC, et al. Tratamento cirúrgico de dentes supranumerários na região anterior da maxila em paciente pediátrico: estudo de caso. *Revista Eletrônica Acervo Saúde*. 2020 Jul 9;12(8):e3494.
18. Shetty AA. *Journal of Advanced Medical and Dental Sciences Research* [Vol. 8|Issue 1]. *J Adv Med Dent Scie Res* [Internet]. 2020;8(1):137–42. Available from: www.jamdsr.com
19. Dixit A, Randhawa G, Randhawa R, Rawal A, Khubchandani R, Rao M. Mesiodens and its complication in anterior maxilla: A case report. *International Journal of Oral Care and Research*. 2019;7(1):27.
20. ANTONIO RC, LIMA IR da S. MESIODENS: DIAGNÓSTICO E INTERVENÇÃO CIRÚRGICA RELATO DE CASO. *UNIFUNEC CIÊNCIAS DA SAÚDE E BIOLÓGICAS*. 2019 Mar 18;2(4).
21. Porcaro G, Mirabelli L, Amosso E. Evaluation of Surgical Options for Supernumerary Teeth in the Anterior Maxilla. *Int J Clin Pediatr Dent*. 2018 Aug;11(4):294–8.
22. Nogueira JSE, Lima ACS, Rodrigues RFS, Nogueira PA, Fonseca RR de S, Cardoso ACC, et al. Tratamento cirúrgico de dentes supranumerários na região anterior da maxila em paciente pediátrico: estudo de caso. *Revista Eletrônica Acervo Saúde*. 2020 Jul 9;12(8):e3494.
23. Vitulli I. REPORTE DE CASO RESUMEN [Internet]. Available from: <https://publicaciones.svrid.org.ve/index.php/rid>

24. Sarne O, Shapira Y, Blumer S, Finkelstein T, Schonberger S, Bechor N, et al. Supernumerary teeth in the maxillary anterior region: The dilemma of early versus late surgical intervention. *Journal of Clinical Pediatric Dentistry*. 2018;42(1):55–61.
25. Shetty AA. *Journal of Advanced Medical and Dental Sciences Research* [Vol. 8|Issue 1]. *J Adv Med Dent Scie Res* [Internet]. 2020;8(1):137–42. Available from: www.jamdsr.com.