

UCUENCA

Facultad de Odontología

Especialización en Ortodoncia

**“SKELETAL AND DENTOALVEOLAR EFFECTS USING CBCT TOOTH-BORNE,
TOOTH-BONE-BORNE, BONE-BORNE, TISSUE BONE-BORNE RME
APPLIANCES: A NARRATIVE REVIEW”**

Trabajo de titulación previo a la
obtención del título de
Especialista en Ortodoncia

Modalidad: Artículo científico

Autor:

Cristian Andrés Imbaquingo Sichel

CI:1003268594

Correo electrónico: odcristian@hotmail.com

Directora:

Miriam Verónica Lima Illescas

CI: 0103711925

Cuenca, Ecuador

31-octubre-2022

Resumen:

CONTEXTO: En el sistema estomatognático, encontramos alteraciones a nivel transversal del maxilar superior las cuales pueden ser tratadas con dispositivos de expansión con anclaje dental y esquelético, estos presentan ventajas o desventajas de acuerdo a su diseño y edad esquelética.

OBJETIVO: Esta revisión narrativa analiza la literatura científica de los efectos de la expansión rápida maxilar dento-soportada y esquelética mediante el uso de tomografía computarizada de haz cónico. (CBCT)

MATERIALES Y MÉTODOS: Se realizó una búsqueda exhaustiva en las bases de datos digitales para encontrar publicaciones relevantes. Se buscó información en los idiomas inglés, español y portugués. La búsqueda se realizó en: Pubmed, Springerlink, Google Academic, Scielo. Se excluyeron artículos como editoriales, reseñas de literatura, cartas al editor, estudios experimentales con animales y las comunicaciones breves. Se incluyeron estudios como casos control, revisiones sistemáticas, casos clínicos y metaanálisis.

RESULTADOS: Inicialmente, se identificaron y revisaron 240 artículos para determinar su relevancia. 199 estudios fueron excluidos al no cumplir los criterios de elegibilidad. 41 estudios fueron incluidos, entre ellos 8 revisiones sistemáticas de las cuales 2 se extrajeron datos de mayor relevancia, 1 estudio prospectivo, 19 ensayos clínicos, 1 reporte de caso, 1 estudio de elementos finitos, 1 estudio descriptivo, 1 estudio piloto, 9 estudios retrospectivos se procesaron para la extracción de datos.

CONCLUSIONES: Los dispositivos tipo MARPE tienen mayor efecto esquelético en relación a los dento-soportados, y menores efectos secundarios dento-alveolares, sin embargo, dichos efectos dependen de la edad esquelética del individuo, el diseño y el sitio de colocación.

Palabras claves: Procedimientos de Ortodoncia de Anclaje. Marpe. Técnica/Efectos de Expansión Palatal. Expansión Maxilar Rápida. Molar. Maxilar

Abstract:

CONTEXT: In the stomatognathic system, there are alterations at the transverse level of the upper jaw which can be treated with expansion devices with dental and skeletal anchorage, these have advantages or disadvantages according to their design and skeletal age.

OBJECTIVE: This narrative review analyzes the scientific literature on the effects of dental-supported and skeletal rapid maxillary expansion with the use of cone beam computed tomography (CBCT).

MATERIALS AND METHODS: An exhaustive search of digital databases was carried out to find relevant publications. Information was searched in English, Spanish and Portuguese. The search was performed in Pubmed, Springerlink, Google Academic, and Scielo. Articles such as editorials, literature reviews, letters to the editor, experimental animal studies and short communications were excluded. Studies such as case controls, systematic reviews, clinical cases, and meta-analyses were included.

RESULTS: Initially, 239 articles were identified and reviewed for relevance. One hundred ninety-nine studies were excluded as they did not meet the eligibility criteria. Forty-one studies were included, among them, 8 systematic reviews from which 2 were extracted data of major relevance, 1 prospective study, 19 clinical trials, 1 case report, 1 finite element study, 1 descriptive study, 1 pilot study, 9 retrospective studies were processed for data extraction.

CONCLUSIONS: MARPE-type devices have a greater skeletal effect to dental-supported devices, and fewer dental-alveolar side effects, however, these effects depend on the skeletal age of the individual, the design and the placement site.

Keywords: Orthodontic Anchorage Procedures. MARPE. Palatal Expansion Technique/Effects. Rapid maxillary expansion. Molar. Maxilla.

Índice

1. INTRODUCTION.....	7
2. MATERIALS AND METHODS	8
2.1 Selection of studies	8
3. Results.....	9
3.1 Rapid Maxillary Expansion Devices (RME)	9
3.1.1 Expansion devices without skeletal anchorage	9
3.2 Expansion devices with mini-screws.....	9
3.2.1 MARPE device design.....	9
3.2.2 Tooth- and bone-supported jaw expansion devices (MSE)	10
3.2.3 Bone and tissue-supported jaw expansion device (C - EXPANDER)	10
3.2.4 Bone-supported jaw expansion device.....	11
3.2.5 Dresden Bone Anchored RME	12
3.3 ACTIVATION	13
4. Dental and skeletal alveolar effects of HYRAX vs. MARPE	13
4.1 Alveolar changes.....	13
4.1.1 Loss of alveolar height at the level of the first permanent molars.	13
4.1.2 Loss of vestibular alveolar bone width at the level of the first permanent molars ..	14
4.1.3 Flexion of the alveolar bone	14
4.2 Dental changes	14
4.2.1 Buccal inclination of the first permanent molars.	14
4.2.2 Intermolar width	15
4.3 Skeletal Changes.....	15
4.3.1 Palatine width	15
4.3.2 Nasal floor width	15
5. DISCUSSION.....	16
6. LIMITATIONS	19
7. CONCLUSIONS	20
RECOMMENDATIONS	21
ANNEXES	22
REFERENCES	24

Cláusula de licencia y autorización para publicación en el Repositorio Institucional

Cristian Andrés Imbaquingo Sichel en calidad de autor y titular de los derechos morales y patrimoniales del trabajo de titulación "SKELETAL AND DENTOALVEOLAR EFFECTS USING CBCT TOOTH-BORNE, TOOTH-BONE-BORNE, BONE-BORNE, TISSUE BONE-BORNE RME APPLIANCES: A NARRATIVE REVIEW", de conformidad con el Art. 114 del CÓDIGO ORGÁNICO DE LA ECONOMÍA SOCIAL DE LOS CONOCIMIENTOS, CREATIVIDAD E INNOVACIÓN reconozco a favor de la Universidad de Cuenca una licencia gratuita, intransferible y no exclusiva para el uso no comercial de la obra, con fines estrictamente académicos.

Asimismo, autorizo a la Universidad de Cuenca para que realice la publicación de este trabajo de titulación en el repositorio institucional, de conformidad a lo dispuesto en el Art. 144 de la Ley Orgánica de Educación Superior.

Cuenca, 31 de octubre del 2022



Cristian Andrés Imbaquingo Sichel

C.I: 1003268594

Cláusula de Propiedad Intelectual

Cristian Andrés Imbaquingo Sichel, autor del trabajo de titulación "SKELETAL AND DENTOALVEOLAR EFFECTS USING CBCT TOOTH-BORNE, TOOTH-BONE-BORNE, BONE-BORNE, TISSUE BONE-BORNE RME APPLIANCES: A NARRATIVE REVIEW", certifico que todas las ideas, opiniones y contenidos expuestos en la presente investigación son de exclusiva responsabilidad de su autor.

Cuenca, 31 de octubre del 2022



Cristian Andrés Imbaquingo Sichel

C.I: 1003268594

1. INTRODUCTION

Rapid Maxillary Expansion (RME) is a routine procedure for the correction of transverse maxillary defects.^{1,2} Although, in general, RME has been recognized as a safe and reliable treatment in growing patients,³ It can cause alveolar flexion and buccal inclination of the affected teeth, which can favor the appearance of collateral periodontal effects, such as loss of bone thickness and marginal bone level, vestibular inclination of the crown in upper molars, extrusion of molars and greater dental expansion than skeletal expansion.^{4,5}

Therefore, the RME device with bone anchorage was introduced in an attempt to reduce or eliminate dental side effects and increase the skeletal expansion ratio.^{6,7} Microimplant Assisted Rapid Palatal Expansion with Bone Anchorage (MARPE) was proposed by Lee et al. in 2010⁸, to avoid adverse dentoalveolar effects and to allow palatal expansion in patients with late skeletal maturation.^{9,10}

The feasibility and predictability of this treatment in patients with advanced skeletal maturation remain controversial due to the increased bony strength of the palatal sutures in late adolescence and a possible dental-periodontal effect of RME.¹¹ Surgically Assisted Rapid Maxillary Expansion (SARME) has been recommended as a treatment option in these cases,¹² However, increased morbidity and cost issues have resulted in poor patient acceptability. Recently, a mini-screw-assisted rapid palatal expansion procedure was proposed,¹³ (MARPE) which allows transverse skeletal correction without severe periodontal side effects in anchored teeth and the biological damage caused by SARME,¹⁴ the load is distributed directly on the upper jaw, there is less rotation and tilt of the jaw complex and less stress on the supporting tissue.⁴

Fundamentally, the use of CBCT allows for providing accurate information on how expansion affects skeletal, dental and periodontal structures, thus CBCT has become safe and simple for planning mini-screw placement in all orthodontic cases requiring skeletal anchorage.^{15,16}

In this review, the objective was to analyze the scientific literature on the effects of rapid dental-supported and skeletal maxillary expansion with the use of cone beam computed tomography (CBCT).

2. MATERIALS AND METHODS

An exhaustive search of the electronic database was carried out to find relevant publications. Information was searched in English, Spanish and Portuguese. The keywords used were (Orthodontic Anchorage Procedures OR MARPE) AND (Palatal Expansion Technique/Effects OR Rapid maxillary expansion) AND (Molar) AND (Maxilla). The search was performed in the following databases: Pubmed, Springerlink, Google Academic, and Scielo. Studies such as systematic reviews, prospective studies, clinical trials, case reports, descriptive studies, and retrospective studies were included. Articles such as editorials, literature reviews, letters to the editor, experimental animal studies and short communications were excluded.

2.1 Selection of studies

Initially, 239 articles were identified and reviewed for relevance. One hundred ninety-nine studies were excluded based on eligibility criteria. Forty-one studies were included, including 8 systematic reviews from which 2 were extracted data of major relevance, 1 prospective study, 19 clinical trials, 1 case report, 1 finite element study, 1 descriptive study, 1 pilot study, 9 retrospective studies were processed for data extraction, and 1 retrospective study was processed for data extraction.

3. Results

3.1 Rapid Maxillary Expansion Devices (RME)

3.1.1 Expansion devices without skeletal anchorage

The studies reviewed evaluated the Hyrax device, which consists of a horizontal screw secured to the maxillary molars and premolars with orthodontic bands connected by 0.036" steel wire. In this treatment, heavy force is applied to the anchored teeth beyond the limits required for orthodontic movement, resulting in hyalinization of their periodontal ligament and thus transferring the load to the maxilla, allowing the opening of the mid-palatal suture.⁴

3.2 Expansion devices with mini-screws

In the systematic review and meta-analysis, Copello et al.⁴ refer that "MARPE devices have been recommended as a suitable therapy for the correction of a transverse maxillary deficiency in patients in whom the mid palatal suture is partially or fused".

To enhance expansion and reduce dental side effects, several types of skeletally anchored RMEs have been developed. These devices can provide different results depending on their design and the activation protocol.¹⁷

Lee et al.⁸ in 2010, described for the first time the efficacy in the palatal expansion of a mini hybrid screw and tooth-anchored expander (MARPE) in a single case report of a 20-year-old individual. Coloccia et al.¹⁵, in a systematic review state, that "Maxillary expansion has evolved in recent years. It shows that hybrid anchorage expansion with two mini-screws and anchorage of upper first molars did not show the undesirable effect of excessive dentoalveolar expansion, so it was considered an alternative method to SARPE (Surgically Assisted Rapid Palatal Expansion) in late adolescents in need of skeletal expansion". After 10 years, a recent meta-analysis confirmed that "mini-screw assisted rapid palatal expansion (MARPE) could decrease buccal alveolar bone loss compared to conventional palatal expansion"⁴

3.2.1 MARPE device design

Tooth-supported RME devices (Hyrax)^{18–20,21,22,23,24}, supported by bone^{18–20}, supported by teeth and bone (MSE)^{25,24,26,27,28,29} and the bone and tissue supported (C-Expander)^{25,23,30} behave differently. In addition, the position of the expander can alter the fulcrum position and expansion pattern, which is essential to understanding the expansion configuration of each device.³¹

3.2.2 Tooth- and bone-supported jaw expansion devices (MSE)

The Maxillary Skeletal Expander (MSE) is a particular type of MARPE device that differs from the others because it promotes the bicortical coupling of the four mini-screws on the palate bone and the nasal floor.²⁷

Moon et al.²⁵ describe that the tooth and bone-supported maxillary expansion device is composed of four stainless steel arms between 1.5mm and 1.8mm in diameter welded to the molar bands to stabilize the MSE and an expansion screw to stabilize the posterior tooth segment. Four custom stainless-steel tubes, (inner diameter: between 1.8mm and 2.0 mm; outer diameter: 3.0 mm; length: 3.0 mm) laser welded directly or indirectly to the leveling screw body. This device has four 1.5 mm diameter, 11 mm long mini-screws placed in the posterior part of the palate with bicortical anchorage (Figure 1).

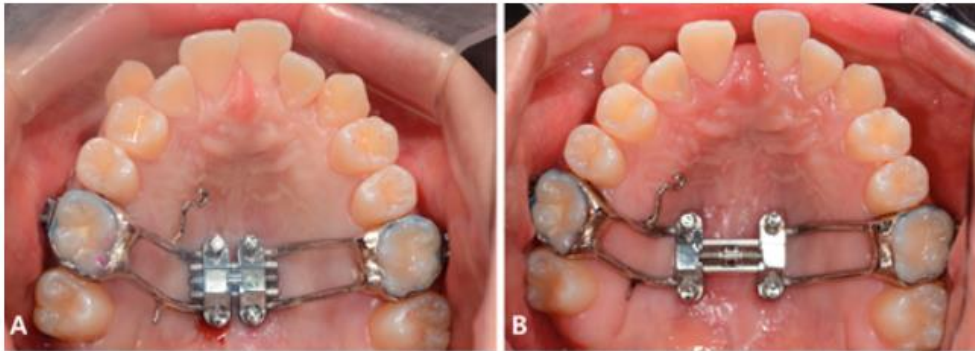


Figure 1. Tooth bone-borne maxillary expander MSE. A: before RME. B: after RME. Reproduced from Moon et al. 2019²⁵, with permission from EH Angle Orthodontists Research & Education Foundation, INC

3.2.3 Bone and tissue-supported jaw expansion device (C - EXPANDER)

The bone and tissue supporting the maxillary expansion device distribute the force to the palatal tissue and basal bone. It is composed of an expansion screw supported by four mini-screws, with a diameter of 1.8 mm and a length of 8.5 mm implanted through the acrylic part of the expander. Two anterior mini-screws are placed between the canines and the first premolars and two posterior mini-screws between the second premolars and the first molars²⁵ (Figure 2).

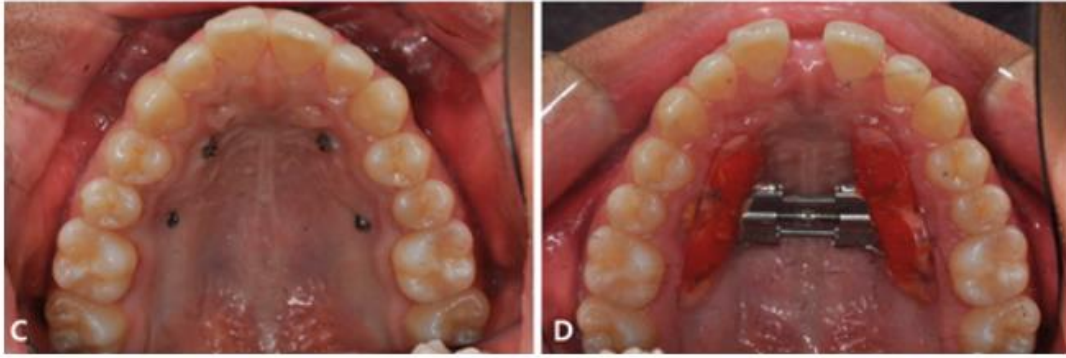


Figure 2. Tissue bone-borne maxillary expander (C-expander) before treatment (C) and after expansion (D). Reproduced from Moon et al. 2019²⁵ with permission from EH Angle Orthodontists Research & Education Foundation, INC

In the study by Lee et al.³² in terms of stress distribution, an RME supported by bone and tissue (C-Expander) placed on the palatal slope showed the lowest stress concentrations without buccal tilt of the dentition compared to other types of RMEs, including a bone RME with mini-screws placed near the mid-palatal suture.

3.2.4 Bone-supported jaw expansion device

Celenk-Koka et al.¹⁸ mention that the device has two expansion screw extension arms that were placed and laser-welded onto the copings in the laboratory, the appliances were mechanically inserted into the heads of the miniscrews and retained by friction. Four miniscrews (1.8 mm × 9 mm, Orlus, Ortholution Co, Seoul, Korea) were placed at a palatal distance of 6 to 8 mm from the gingival margin of the teeth with perpendicular insertion into the alveolar bone between the roots using a contra-angle handpiece (Unitek REF 504-315, 3M Unitek, Monrovia, California). The anterior mini-screws were placed bilaterally between the roots of the first and second premolars, and the posterior mini-implants were placed between the roots of the second premolars and first molars (Figure 3).

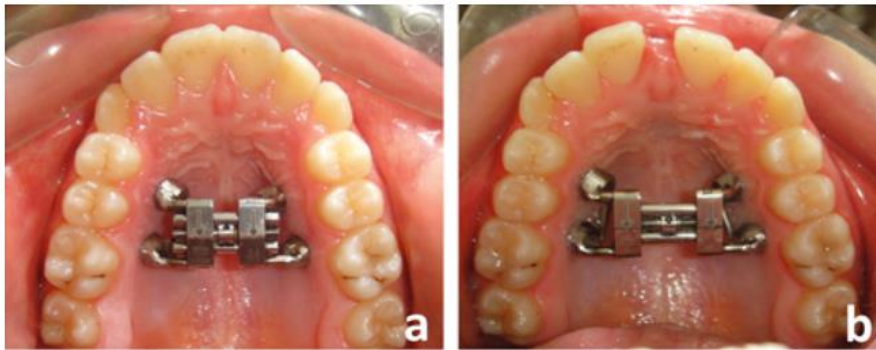


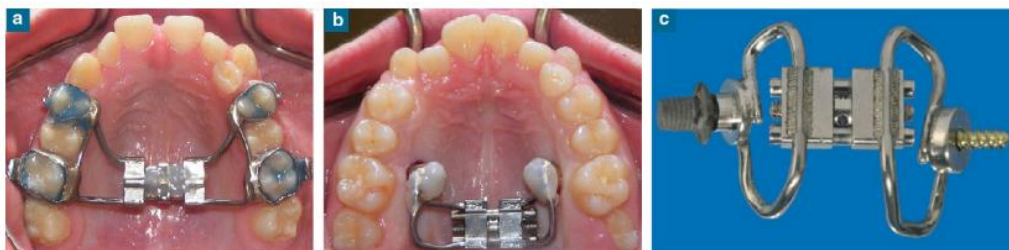Figure 3. Pre- (a) and post-expansion (b) occlusal photographs of a patient from the miniscrew-supported (bone-borne) RME group. Reproduced from Celenk Koca et al. 2018¹⁸

Celenk - Koca et al.,¹⁸ report that these new expander designs offer more bone anchorage than traditional RMEs on teeth; however, the results varied significantly from device to device due to the difference in device design. Even with bone anchorage, significant dentoalveolar changes have been reported in several MARPE studies.^{31,33,34}

Clinical control studies demonstrated that placing the expansion screw in the posterior part of the palate, medial to the zygomatic buttresses, distributes the separation force along the entire length of the suture and thus promotes a more parallel division.^{27,31}

3.2.5 Dresden Bone Anchored RME

Lagravère et al.²¹ report that it was first used in Germany for the correction of maxillary constriction in adults undergoing surgical EMR, as reported by Tausche et al.^{21,35} is a design supported by a palatal implant on one side and a mini-screw on the other side.



Taken from Lagravère et al.²¹ a) tooth-anchored; b) bone-anchored expander; c) Dresden B-RME: Mini-Hyrax jackscrew supported by palatal implant (implant-side) on one side and TAD (TAD- side) on the other

3.3 ACTIVATION

According to Coloccia et al.¹⁵ in the systematic review describes that the activation protocols in MARPE were almost the same in 10 studies ^{18–22,24,27,28,30,31}, being two-quarters of a round per day. But the amount of expansion was different for all studies because it depends on the amount of skeletal discrepancy. It is important to emphasize that different types of MARPE devices were used in these studies. Finally, all studies described that the end of activation is when the occlusal contact between the palatal cusps of the upper posterior teeth and the vestibular cusps of the lower posterior teeth were overcorrected by the skeletal discrepancies.

Cantarella et al.²⁷ in 15 subjects with a mean age of 17.2 years; range, 13.9-26.2 years indicates that the expansion rate was two quarter turns per day (0.25 mm each) until an inter-incisal space appeared, then activation was performed once per day which corroborates Moon et al.²⁵ After the expansion, the MARPE remained blocked for at least 3 months to stabilize the expansion.

Zong et al.²⁶ suggest starting maxillary expansion 2 weeks after mini-screw placement and the rate of activation depends on the chronological age of the patient, as Copello et al.⁴ report that the screw opening started after a healing period of seven days after the insertion of the anchorage devices.

4. Dental and skeletal alveolar effects of HYRAX vs. MARPE

The studies mentioned in the manuscript report that the greatest effects are produced on the height, width and flexion of the alveolar bone, as well as on the intermolar inclination and width and on palatal and nasal expansion, which are detailed below.

4.1 Alveolar changes

4.1.1 Loss of alveolar height at the level of the first permanent molars.

A systematic review conducted by Khosravi et al.³⁶, where the inclusion criteria are patients over 18 years of age, the evidence shows that in MARPE the loss of alveolar ridge height is from 0.24 mm to 1.24 mm.

Jia et al.^{17,29} report that there is greater benefit in the use of bone- and tooth-supported devices, comparing the MSE versus the Hyrax they found 0.4mm on the right side; 0.7mm on the left side and 1.56 right; 1.95 left respectively.

While Moon et al.²⁵ report that the devices supported by tissue and bone (C-Expander) have less reduction of alveolar height $p < 0.01$ compared to the MSE (Table 2).

4.1.2 Loss of vestibular alveolar bone width at the level of the first permanent molars

In 28 patients who participated in a controlled clinical study conducted by Lin et al.²³ In the C-expander group and Hyrax group, there was a less alveolar bone loss, but it was not significant ($p > 0.05$).

However, Celenk-Koca et al.¹⁸ a lower loss of vestibular alveolar bone was observed, being statistically significant $p < 0.01$ in the group treated with the bone-supported device compared to Hyrax for both premolars and molars (Table 1).

4.1.3 Flexion of the alveolar bone

Lin et al.²³ observed that alveolar flexion was 2 times more in the Hyrax group compared to the C-expander group except in the second molar region (Table 2).

Whereas Moon et al.²⁵ the group treated with the MSE presented less flexion of the alveolar bone at 0.74° compared to the C expander at 2.18° (Table 2).

Bazargani et al.²⁴ found greater alveolar bone bending effects on the palatal slopes on the right side and less on the left side comparing the MSE with the Hyrax device, the authors concluded that there was no significant difference ($p=0.78$) ($p=0.41$) between the two groups (Table 3).

4.2 Dental changes

4.2.1 Buccal inclination of the first permanent molars.

Bazargani et al.²⁴ indicate that on the right side there was greater inclination, while on the left side it was less, when purchasing the MSE with the Hyrax devices, however, there was no statistical difference $p < 0.05$ between the two groups of dental-supported (Hyrax) and tooth and bone supported (MSE) on alveolar inclination after 1 year (Table 3).

Some studies^{23,21,20,18} show that molar inclination was significantly higher with the Hyrax device compared to bone-supported, bone-tooth-supported and bone-tissue-supported devices (Tables 1,2,3).

4.2.2 Intermolar width

Lin et al.²³ determined that the intermolar width at the level of the crowns was greater in the Hyrax device (2.3 ± 1.2 mm) than in the C-expander (Table 2).

Mehta et al.^{19,21} The bone-supported device presented a greater intermolar width (5.24 mm) than the Hyrax group (4.2 mm), which is not statistically significant (Table 1).

On the contrary, Kavand et al.²⁰ found that the intermolar width was greater in Hyrax devices compared to bone-supported devices ($p= 0.3241$).

4.3 Skeletal Changes

4.3.1 Palatine width

Mehta et al.¹⁹ found greater palatal width with the bone-supported devices (2.07 mm) than the Hyrax (1.1 mm) which is statistically significant, (Table 1) while Kavand et al.²⁰ compared palatal width, which was greater in the bone-supported devices than in the Hyrax group, but there was no significant difference ($p > 0.05$).

4.3.2 Nasal floor width

Celenk Koca et al.¹⁸ report that there was a significant difference in nasal floor width using the bone-supported devices (2.9 ± 1.7 mm) compared to the Hyrax group (1.2 ± 1.1).

While Bazargani et al.²⁴ used the Dresden Bone-Borne device and Lagravère et al.²¹ the device supported by bone and teeth, and finding greater expansion in the width of the nasal floor, despite this, both authors found no significant differences (Table 4 and Table 3) which is corroborated by Khosravi et al.³⁶ and Lagravère et al.²¹ which presented similar results in dental and skeletal expansion but did present a significant difference in comparison with the control group.

5. DISCUSSION

In this narrative review, it was decided to classify and group the data obtained by device design, which are shown in Tables 1, 2, 3 and 4 to obtain more accurate results.

Three of the selected studies compared the bone-anchored MARPE device alone and the Hyrax device with dental anchorage.¹⁸⁻²⁰

Celenk Koca et al.¹⁸ showed that in patients 13.69 ± 1.74 years of age, no statistically significant differences in intermolar width were found (Table 1), coinciding with Metha et al.¹⁹ y Kavand et al.²⁰ Several factors may have influenced the results mentioned above, among them, it is important to highlight that being in adolescence and not yet having skeletal maturity is an advantage for Hyrax.

In the palatine width, Metha et al.¹⁹ and Celenk Koca et al.^{18,20} observed that the device transmitted by bone anchorage provided greater expansion at the level of the palatal suture being statistically significant, likewise Kavand et al.²⁰ The results indicate that in the width of the nasal floor they found greater effectiveness in the bone anchorage device with a value of $p > 0.05$.

While in the external maxillary width located in the depth of the concavity of the lateral external walls of the maxillary sinuses Metha et al.^{19,20} and Kavand et al.²⁰ agree that expansion presented similar results in the bone-supported and tooth-supported device with no significant statistical difference.

It is worth mentioning that decreased buccal alveolar bone thickness and the presence of bone dehiscences are commonly reported after routine EMR, especially in anchorage teeth, such effects are caused by osteoclast resorption that occurs when the teeth cross the vestibular table.³⁷⁻⁴⁰

Celenk Koca et al.¹⁸ demonstrate that in the devices with skeletal anchorage there is less loss of buccal alveolar bone being -0.10 ± 0.1 while the conventional RME - 0.24 ± 0.2 with a statistically significant difference $p < 0.05$.

It has been reported that almost half of the expansion obtained at the alveolar level after an RME procedure is due to alveolar flexion towards the vestibular.⁴¹ The same occurs with some MARPE devices, the maxillary halves show a buccal rotation, with the center of rotation located near the frontonasal suture.⁴¹ For this reason, buccal tooth inclination and alveolar flexion occur. However, Celenk Koca et al.¹⁸ indicate that alveolar bending is lower $p < 0.05$ in bone-borne devices.

Regarding molar inclination in this group, only Kavand et al.²⁰ take this measure into account and add that it was higher in the device with dental anchorage, the results being higher on the right side than on the left and statistically significant.

Among the articles found two of them reported by Lagravère et al.²¹ and Davami et al.²² use the Dresden Bone-anchored Maxillary Expansion and the Hyrax Rapid Palatal Expansion in 13-14-year-old patients.²¹

In the results found Lagravère et al.²¹ state that the intermolar width is greater in the Hyrax type dental anchorage device, where $p < 0.05$, while Davami et al.²² (Table 4) The Dresden type device presents greater intermolar width, although no statistically significant difference was found between the two devices. This finding may be because they take different brands to measure the intermolar width or that the device does not present a greater benefit.

Regarding the width of the nasal floor, according to Lagravère et al.²¹ similar values between both devices, Type Dresden 1.31 mm followed by Hyrax 1.27 mm (Table 4).

Regarding the width of the vestibular alveolar bone at the molar level, Lagravère et al.²¹ indicate that there is no statistically significant difference in the dental and skeletal anchorage devices, being greater in the Dresden type device at 1.51mm and Hyrax at 1.40mm, otherwise, Davami et al.²² reports that the skeletal anchorage device has less reduction of the vestibular alveolar bone width (1.74 ± 2.48) while the dental anchorage device shows 3.11 ± 2.18 mm, however, Davami et al.²² does not indicate the p -value. Both treatment groups showed a slightly asymmetric expansion. Dental asymmetry in the Hyrax device was greater than in the Dresden type, especially in the premolar area.

The systematic review by Copello et al.⁴, shows that the width or thickness of the alveolar bone is smaller in the MARPE devices, being $SMD=0.55$; $95\% CI: 0.29-0.80$; $p < 0.0001$, however, the author clarifies that the quality of evidence is low.

Cantarella et al.²⁷ describe only the dental and skeletal anchorage device (MSE) without comparing it with another and it is observed in individuals 13.9-26.2 years of age that there was an expansion of 4.75 ± 2.59 at the level of the anterior nasal spine and 4.33 ± 1.74 at the level of the posterior nasal spine, an additional data revealed by this article is the separation of the right (1.35 ± 1.79) and left (2.17 ± 2.45) pterygo maxillary process demonstrating the skeletal effect on the adjacent sutures.

On the other hand, in the study conducted by Moon et al.²⁵ comparing the MSE devices with the C-Expander in subjects between 18 and 19 years of age, it was observed that there was a statistically significant difference in the intermolar width,

with greater dentoalveolar expansion in the devices supported by bone and teeth (4.91mm) than in the devices supported by bone and tissue (4.01mm) $p<0.05$.

Molar inclination was higher for the group treated with bone- and tooth-supported devices; another study presents similar results,²⁹ this may be due to stress accumulating on the anchor teeth and hard palate and the diameter of the microimplants was 1.5 and the holes for the microimplants in the expansion devices were 2 mm in diameter causing an initial direct load on the teeth.^{26,29}

Meanwhile, the alveolar inclination was higher for the group supported by bone and tissue (1.4°) compared to those supported by bone and teeth (0.2°) being statistically significant, similar results showed in other studies.^{23,30}

In terms of external maxillary expansion there was no statistically significant difference between bone and tooth-supported devices (2.45mm) and bone and tissue-supported devices (2.38mm), so both devices generate similar expansions (Table 2).

But when comparing bone- and tissue-supported devices with tooth-supported devices (Hyrax), as in the study of Lin et al.²³ in which subjects between 17 and 18 years of age participated, the Hyrax devices achieved greater intermolar width ($p=0.035$).

The amount of alveolar bone flexion towards the vestibular was more than twice as much in the group treated with tooth-supported devices than the bone and tissue-supported devices with statistically significant values ($p=0.027$), this greater alveolar bone flexion in the dental anchorage devices is due to the two halves of the maxillary bone being rotated, with the central expansion vector at the frontonasal suture in the coronal plane.³¹

The skeletal changes that occur according to Bazargani et al.²⁴ when expansion is performed in patients aged 9.3 ± 1.3 years are greater for patients treated with bone and tooth-supported devices (2.3mm) while those with tooth-supported devices (1.8mm). As for the alveolar inclination when comparing the bone and tooth-supported (5.4° right and -3.5° left) it was greater than the tooth-supported (5° right and 4.5° left) and no statistically significant difference was found between the two groups. The molar inclination showed that the bone and tooth-supported molar inclination was lower on the left side and higher on the right side.²⁴

Likewise, Khosravi et al.³⁶ who conducted a recent systematic review found that both tooth-supported and tooth and bone-supported devices give the same results in terms of quantity in terms of tooth inclination.

6. LIMITATIONS

In the present investigation, limited literature was found in which jaw expansion was compared with devices of the same design, age, activation, and benchmarks to measure the effects produced.

7. CONCLUSIONS

It was found that in the bone-supported devices there was greater expansion in the external maxillary, intermolar and palatal width in patients aged 13.69 ± 1.74 compared to those aged 14.7 ± 1.4 .

Palatal width is greater and alveolar bone width loss is less in bone-supported devices, while alveolar flexion and molar tilt are less in bone- and tissue-supported devices. Limited evidence was found.

As for the Dresden-type expansion device, due to its complexity in design, elaboration and limited results, its use in the clinic would present difficulties.

The findings found when comparing the devices supported by bone and tooth presented greater intermolar width and inclination compared to the devices supported by bone and tissue, which presented greater alveolar inclination.

In the tooth and bone-supported devices, there is not enough scientific evidence on alveolar and molar inclination, however, the scarce evidence found indicates that there are different values on the right and left sides and it is greater in the Hyrax.

Both bone and tissue-supported devices and tooth and bone-supported devices have a greater skeletal effect than Hyrax.

It is essential to individualize the maxillary compression characteristics to choose the device design and optimize its effects.

RECOMMENDATIONS

To deepen the changes obtained in the long-term dental alveolar and skeletal effects.

ANNEXES

Table 1. Comparison between RME TOOTH-BORN and BONE-BORNE devices

AUTHOR	Celenk-Koca, T., Erdinc, A. E., Hazar, S., Harris, L., English, J. D., & Akyalcin, S. (2018).		Mehta, S., Wang, D., Kuo, C. L., Mu, J., Vich, M. L., Allareddy, V., Tadinada, A., & Yadav, S. (2021)		Kavand, G., Lagravère, M., Kula, K., Stewart, K., & Ghoneima, A. (2019).	
STUDY DESIGN	Randomized clinical trial		Randomized controlled trial		Retrospective Study	
SAMPLE	40		60		36	
APPLIANCE	Bone - Borne	Tooth - borne (Hyrax)	Bone - Borne	Tooth - borne (Hyrax)	Bone - Borne	Tooth - borne (Hyrax)
AGE	13.81 ± 1.23	13.84 ± 1.36	13.69 ± 1,74	13.9 ± 1,14	14.7 ± 1.4	14.4 ± 1.3
Intermolar Width (mm)	4.5 ± 1.3	4.2 ± 1.7	5.24	4.2	3.1±1.2	4.5±0.4
<i>p</i>	0,52		0,382		0,3241	
Palatal Width (mm)	-	-	2.07	1.1	2.2±0.3	1.5±0.4
<i>p</i>	-		0,001		0,0840	
Nasal Floor Width (mm)	2,9±1.7	1,2±1.1	-	-	-	-
<i>p</i>	0,001		-		-	
External Maxillary Width (mm)	-	-	1.47	1.27	1.7±0.4	2.2±0.4
<i>p</i>	-		0,748		0,3493	
Buccal bone thickness R (mm)	-0,10±0,1	-0,24±0,2	-	-	-	-
<i>p</i>	0,046		-		-	
Alveolar Inclination R (mm)	1.3 ± 2.1	-3.9 ± 3.4	-	-	-	-
<i>p</i>	0,000		-		-	
Tooth Inclination R (mm)	-	-	-	-	0,4±0,9	3,0±0,7
<i>p</i>	-		-		0,0446	
Tooth Inclination L (mm)	-	-	-	-	1,4±0,7	2,3±0,7
<i>p</i>	-		-		0,3671	

Table 2 Description RME TOTH BONE-BORNE & TISSUE BONE BORNE; TOOTH-BORNE & TISSUE BONE BORNEW appliances

AUTHOR	Moon, H. W., Kim, M. J., Ahn, H. W., Kim, S. J., Kim, S. H., Chung, K. R., & Nelson, G. (2020)		Lin, L., Ahn, H. W., Kim, S. J., Moon, S. C., Kim, S. H., & Nelson, G. (2015)	
STUDY DESIGN	Retrospective study		Retrospective study	
SAMPLE	48		28	
APPLIANCE	Tooth bone-borne	Tissue bone-borne	Tooth - borne (Hyrax)	Tissue bone-borne (C-expander)
AGE	19,2	18,1	17,4	18,1
Intermolar Width (mm)	4,91	4,01	4,45	3,46
<i>P</i>	0,040		0,035	
External Maxillary Width (mm)	2,45	2,38		
<i>P</i>	0,859			
Palatal Width (mm)	-	-	1,14±0,47	1,99±1,18
<i>P</i>	-		0,0043	
Buccal bone thickness R (mm)	-0,67	-0,13		
<i>P</i>	0,000			
Alveolar Inclination R (mm)	0,74	2,18	3,62	1,43
<i>P</i>	0,004		0,0277	
Alveolar Inclination L (mm)	0,88	2,35	3,67	0,66
<i>P</i>	0,001		0,0083	
Tooth Inclination R (mm)	2,77	0,10	5±2.35	1,16±1.2
<i>P</i>	0,000		0,0001	
Tooth Inclination L (mm)	2,03	0,03	8.09±5.86	1,15±1.05
<i>P</i>	0,001		0,0011	
Buccal Dehiscence R (mm)	1,15	0,13	0,44	0,11
<i>P</i>	0,010		0,0000	
Buccal Dehiscence L (mm)	1,51	0,03	0,63	0,11
<i>P</i>	0,001		0,0000	
Buccal alveolar bone height loss R	1,15	0,13	-0,91	-0,54
<i>P</i>	0,010		0,279	
Buccal alveolar bone height loss L	1,51	0,03	-0,59	-0,27
<i>P</i>	0,001		0,0381	
Transverse distances of tooth Crown (mm)			4,45	3,46
<i>P</i>			0,0000	
Transverse distances of tooth Apex (mm)			2,79	2,03
<i>P</i>			0,001	

Table 3. Comparison between RME TOTH BONE-BORNE & TOOTH-BORNE

AUTHOR	Bazargani, F., Lund, H., Magnuson, A., & Ludwig, B. (2021)	
STUDY DESIGN	Randomized controlled trial	
SAMPLE	52	
APPLIANCE	Tooth bone-borne (MSE)	Tooth - borne (Hyrax)
AGE	9,3	9,3
Nasal Floor Width (mm)	2.3	1.8
<i>P</i>	0.16	
Buccal bone thickness R (mm)	0.1	0.4
<i>P</i>	0.15	
Buccal bone thickness L (mm)	0.4	0.4
<i>P</i>	0.94	
Alveolar Inclination R (°)	5,4	5
<i>P</i>	0.78	
Alveolar Inclination L (°)	3,5	4,5
<i>P</i>	0.41	
Tooth Inclination R (°)	3.8	3.4
<i>P</i>	0.69	
Tooth Inclination L(°)	2.5	4.7
<i>P</i>	0.009	

Table 4. Changes before and after of RME TOTH BONE-BORNE & TISSUE BONE BORNE appliances.

AUTHOR	Chen Zong, Bojun Tang, Fang Hua, Hong He, Peter Ngan (2019)	Cantarella, D., Dominguez-Mompell, R., Malliya, S. M., Moschik, C., Pan, H. C., Miller, J., & Moon, W. (2017).	Li, Q., Tang, H., Liu, X., Luo, Q., Jiang, Z., Martin, D., & Guo, J. (2020)	Yi, F., Liu, S., Lei, L., Liu, O., Zhang, L., Peng, Q., & Lu, Y. (2020).	Park, J. J., Park, Y. C., Lee, K. J., Cha, J. Y., Tahk, J. H., & Choi, Y. J. (2017)
STUDY DESIGN	-	Retrospective clinical trials			
SAMPLE	22	15	22	19	14
APPLIANCE	Tooth bone-borne (MSE)	Tooth bone-borne (MSE)	Tooth bone-borne (MSE)	Tissue bone-borne (C-Expander)	Tooth bone-borne (MSE)
AGE	14.97 ± 6.16	13,9–26,2	18-35	19.95 ± 4.39	16-26
Intermolar Width (mm)	5.41±2.18	-	-	3.92±2.36	5,4 +- 1,7
Palatal Width (mm)	3.34±1.75	4,75±2,59 ENA	2,3±1,2	-	-
	-	4,33±1,74 ENP	-	1.25±0.69	-
Nasal Floor Width (mm)	2.28±1.54	-	-	1.77±1.48	-
External Maxillary Width (mm)	-	-	2,0±1,0	1.67±1.17	1.7±1.8
Buccal bone thickness R (mm)	-	-	-	-	-0.6±1.0
Buccal bone height loss (mm)	-	-	-	-	1.7±2.5
Tooth Inclination R	2,33	-	-	-	-
Tooth Inclination L	2,63	-	-	-	-
Width of opening in Rt pterygoid process (mm)	-	1,35±1,79	-	-	-
Width of opening in Lt pterygoid process (mm)	-	2,17±2,45	-	-	-

REFERENCES

1. Pham V, Lagravère MO. Alveolar bone level changes in maxillary expansion treatments assessed through CBCT. *Int Orthod*. 2017 Mar;15(1):103–13.
2. Baysal A, Uysal T, Veli I, Ozer T, Karadede I, Hekimoglu S. Evaluation of alveolar bone loss following rapid maxillary expansion using cone-beam computed tomography. *Korean J Orthod*. 2013 Apr;43(2):83–95.
3. Lione R, Franchi L, Cozza P. Does rapid maxillary expansion induce adverse effects in growing subjects? *Angle Orthod*. 2013 Jan;83(1):172–82.
4. Copello FM, Marañón-Vásquez GA, Brunetto DP, Caldas LD, Masterson D, Maia LC, et al. Is the buccal alveolar bone less affected by mini-implant assisted rapid palatal expansion than by conventional rapid palatal expansion? -A systematic review and meta-analysis. *Orthod Craniofac Res*. 2020 Aug;23(3):237–49.
5. An JS, Seo BY, Ahn SJ. Differences in dentoskeletal and soft tissue changes due to rapid maxillary expansion using a tooth-borne expander between adolescents and adults: A retrospective observational study. *Korean J Orthod*. 2022 Mar 25;52(2):131–41.
6. Lim HM, Park YC, Lee KJ, Kim KH, Choi YJ. Stability of dental, alveolar, and skeletal changes after miniscrew-assisted rapid palatal expansion. *Korean J Orthod*. 2017 Sep;47(5):313–22.
7. Gunyuz Toklu M, Germec-Cakan D, Tozlu M. Periodontal, dentoalveolar, and skeletal effects of tooth-borne and tooth-bone-borne expansion appliances. *Am J Orthod Dentofacial Orthop*. 2015 Jul;148(1):97–109.
8. Lee KJ, Park YC, Park JY, Hwang WS. Miniscrew-assisted nonsurgical palatal expansion before orthognathic surgery for a patient with severe mandibular prognathism. *Am J Orthod Dentofacial Orthop*. 2010 Jun;137(6):830–9.
9. Chun JH, de Castro ACR, Oh S, Kim KH, Choi SH, Nojima LI, et al. Skeletal and alveolar changes in conventional rapid palatal expansion (RPE) and miniscrew-assisted RPE (MARPE): a prospective randomized clinical trial using low-dose CBCT. *BMC Oral Health*. 2022 Apr 8;22(1):114.
10. Choi SH, Shi KK, Cha JY, Park YC, Lee KJ. Nonsurgical miniscrew-assisted rapid maxillary expansion results in acceptable stability in young adults. *Angle Orthod*. 2016 Sep;86(5):713–20.
11. Angelieri F, Cevidanes LHS, Franchi L, Gonçalves JR, Benavides E, McNamara JA Jr. Midpalatal suture maturation: classification method for individual assessment before rapid maxillary expansion. *Am J Orthod Dentofacial Orthop*. 2013 Nov;144(5):759–69.
12. Vidalón JA, Lou-Gómez I, Quiñe A, Díaz KT, Liñan Duran C, Lagravère MO. Periodontal effects of maxillary expansion in adults using non-surgical expanders with skeletal anchorage vs. surgically assisted maxillary expansion: a systematic review. *Head Face Med*. 2021 Nov 10;17(1):1–12.
13. Chung M, Lyu ZZ, Zhu BK, Wang XJ, Qu RY, Jiang LY. [Effects of mid-palatal suture opening and midfacial bony structure changes induced by maxillary skeletal expansion in adults]. *Shanghai Kou Qiang Yi Xue [Internet]*. 2021 Jun [cited 2022 Aug 1];30(3). Available from: <https://pubmed.ncbi.nlm.nih.gov/34476453/>
14. Tang H, Liu P, Liu X, Hou Y, Chen W, Zhang L, et al. Skeletal width changes after mini-implant-assisted rapid maxillary

- expansion (MARME) in young adults. *Angle Orthod.* 2021 May 1;91(3):301–6.
15. Coloccia G, Inchingolo AD, Inchingolo AM, Malcangi G, Montenegro V, Patano A, et al. Effectiveness of Dental and Maxillary Transverse Changes in Tooth-Borne, Bone-Borne, and Hybrid Palatal Expansion through Cone-Beam Tomography: A Systematic Review of the Literature. *Medicina [Internet]*. 2021 Mar [cited 2022 Apr 22];57(3). Available from: <https://www.ncbi.nlm.nih.gov/pmc/articles/PMC8003431/>
 16. Sawchuk D, Currie K, Vich ML, Palomo JM, Flores-Mir C. Diagnostic methods for assessing maxillary skeletal and dental transverse deficiencies: A systematic review. *Korean J Orthod.* 2016 Sep;46(5):331–42.
 17. Jia H, Zhuang L, Zhang N, Bian Y, Li S. Comparison of skeletal maxillary transverse deficiency treated by microimplant-assisted rapid palatal expansion and tooth-borne expansion during the post-pubertal growth spurt stage:: A prospective cone beam computed tomography study. *Angle Orthod.* 2021 Jan;91(1):36.
 18. Celenk-Koca T, Erdinc AE, Hazar S, Harris L, English JD, Akyalcin S. Evaluation of miniscrew-supported rapid maxillary expansion in adolescents: A prospective randomized clinical trial. *Angle Orthod.* 2018 Nov;88(6):702–9.
 19. Mehta S, Wang D, Kuo CL, Mu J, Vich ML, Allareddy V, et al. Long-term effects of mini-screw–assisted rapid palatal expansion on airway:A three-dimensional cone-beam computed tomography study. *Angle Orthod.* 2020 Dec 14;91(2):195–205.
 20. Kavand G, Lagravère M, Kula K, Stewart K, Ghoneima A. Retrospective CBCT analysis of airway volume changes after bone-borne vs tooth-borne rapid maxillary expansion. *Angle Orthod.* 2019 Feb 15;89(4):566–74.
 21. Lagravère MO, Ling CP, Woo J, Harzer W, Major PW, Carey JP. Transverse, vertical, and anterior-posterior changes between tooth-anchored versus Dresden bone-anchored rapid maxillary expansion 6 months post-expansion: A CBCT randomized controlled clinical trial. *Int Orthod [Internet]*. 2020 Jun [cited 2022 Apr 29];18(2). Available from: <https://pubmed.ncbi.nlm.nih.gov/32057733/>
 22. Kamran D, Talma E, Harzer W, M. L. Long term skeletal and dental changes between tooth-anchored versus Dresden bone-anchored rapid maxillary expansion using CBCT images in adolescents: Randomized clinical trial. *Int Orthod.* 2020 Jun 1;18(2):317–29.
 23. Lin L, Ahn HW, Kim SJ, Moon SC, Kim SH, Nelson G. Tooth-borne vs bone-borne rapid maxillary expanders in late adolescence. *Angle Orthod.* 2015 Mar;85(2):253–62.
 24. Bazargani F, Lund H, Magnuson A, Ludwig B. Skeletal and dentoalveolar effects using tooth-borne and tooth-bone-borne RME appliances: a randomized controlled trial with 1-year follow-up. *Eur J Orthod [Internet]*. 2021 Jun 8 [cited 2022 Apr 28];43(3). Available from: <https://pubmed.ncbi.nlm.nih.gov/32761047/>
 25. Moon HW, Kim MJ, Ahn HW, Kim SJ, Kim SH, Chung KR, et al. Molar Inclination and Surrounding Alveolar Bone Change Relative To the Design of Bone-borne Maxillary Expanders: A Cbct study. *Angle Orthod.* 2019 Aug 28;90(1):13–22.
 26. Zong C, Tang B, Hua F, He H, Ngan P. Skeletal and dentoalveolar changes in the transverse dimension using microimplant-assisted rapid palatal expansion (MARPE) appliances [Internet]. Vol. 25, *Seminars in Orthodontics*. 2019. p. 46–59. Available from: <http://dx.doi.org/10.1053/j.sodo.2019.02.006>

27. Cantarella D, Dominguez-Mompell R, Mallya SM, Moschik C, Pan HC, Miller J, et al. Changes in the midpalatal and pterygopalatine sutures induced by micro-implant-supported skeletal expander, analyzed with a novel 3D method based on CBCT imaging. *Prog Orthod*. 2017 Nov 1;18(1):1–12.
28. Li Q, Tang H, Liu X, Luo Q, Jiang Z, Martin D, et al. Comparison of dimensions and volume of upper airway before and after mini-implant assisted rapid maxillary expansion. *Angle Orthod*. 2020 May 1;90(3):432–41.
29. Park JJ, Park YC, Lee KJ, Cha JY, Tahk JH, Choi YJ. Skeletal and dentoalveolar changes after miniscrew-assisted rapid palatal expansion in young adults: A cone-beam computed tomography study. *Korean J Orthod*. 2017 Mar;47(2):77.
30. Yi F, Liu S, Lei L, Liu O, Zhang L, Peng Q, et al. Changes of the upper airway and bone in microimplant-assisted rapid palatal expansion: A cone-beam computed tomography (CBCT) study. *J Xray Sci Technol*. 2020;28(2):271–83.
31. Paredes N, Colak O, Sfogliano L, Elkenawy I, Fijany L, Fraser A, et al. Differential assessment of skeletal, alveolar, and dental components induced by microimplant-supported midfacial skeletal expander (MSE), utilizing novel angular measurements from the fulcrum. *Prog Orthod*. 2020 Jul 13;21(1):18.
32. Lee HK, Bayome M, Ahn CS, Kim SH, Kim KB, Mo SS, et al. Stress distribution and displacement by different bone-borne palatal expanders with micro-implants: a three-dimensional finite-element analysis. *Eur J Orthod*. 2014 Oct;36(5):531–40.
33. Ghoneima A, Abdel-Fattah E, Hartsfield J, El-Bedwehi A, Kamel A, Kula K. Effects of rapid maxillary expansion on the cranial and circummaxillary sutures. *Am J Orthod Dentofacial Orthop*. 2011 Oct;140(4):510–9.
34. Olmez H, Akin E, Karaçay S. Multitomographic evaluation of the dental effects of two different rapid palatal expansion appliances. *Eur J Orthod* [Internet]. 2007 Aug [cited 2022 Jul 24];29(4). Available from: <https://pubmed.ncbi.nlm.nih.gov/17702798/>
35. Tausche E, Hansen L, Hietschold V, Lagravère MO, Harzer W. Three-dimensional evaluation of surgically assisted implant bone-borne rapid maxillary expansion: a pilot study. *Am J Orthod Dentofacial Orthop*. 2007 Apr;131(4 Suppl):S92–9.
36. Khosravi M, Ugolini A, Miresmaeili A, Mirzaei H, Shahidi-Zandi V, Soheilifar S, et al. Tooth-borne versus bone-borne rapid maxillary expansion for transverse maxillary deficiency: A systematic review. *Int Orthod*. 2019 Sep;17(3):425–36.
37. Garib DG, Henriques JF, Janson G, de Freitas MR, Fernandes AY. Periodontal effects of rapid maxillary expansion with tooth-tissue-borne and tooth-borne expanders: a computed tomography evaluation. *Am J Orthod Dentofacial Orthop* [Internet]. 2006 Jun [cited 2022 Apr 29];129(6). Available from: <https://pubmed.ncbi.nlm.nih.gov/16769493/>
38. Lo Giudice A, Barbato E, Cosentino L, Ferraro CM, Leonardi R. Alveolar bone changes after rapid maxillary expansion with tooth-borne appliances: a systematic review. *Eur J Orthod*. 2018 May 25;40(3):296–303.
39. Bastos RT da RM, Blagitz MN, Aragón MLS de C, Maia LC, Normando D. Periodontal side effects of rapid and slow maxillary expansion. *Angle Orthod*. 2019 Jul;89(4):651–60.
40. Akyalcin S, Schaefer JS, English JD, Stephens CR, Winkelmann S. A cone-beam computed tomography evaluation of buccal bone thickness following maxillary expansion. *Imaging Sci Dent*. 2013 Jun;43(2):85–90.

41. Weissheimer A, de Menezes LM, Mezomo M, Dias DM, de Lima EMS, Rizzato SMD. Immediate effects of rapid maxillary expansion with Haas-type and hyrax-type expanders: a randomized clinical trial. *Am J Orthod Dentofacial Orthop.* 2011 Sep;140(3):366–76.