

UCUENCA

Facultad de Odontología

Carrera de Odontología

Anatomical characterization of the floor of the mouth: A review of the
literatura

Trabajo de titulación previo a la
obtención del título de
Odontólogo.

Modalidad: Artículo académico.

Autoras:

Maritza Alexandra Esparza Quizhpi

CI:0350063970

Correo electrónico: marithzaesparza@gmail.com

Karla Teresita Segovia Sigüenza

CI: 0105410781

Correo electrónico: karlasegovias@yahoo.com

Tutor:

David Manuel Pineda Álvarez

CI: 0103523916

Cuenca, Ecuador

20-septiembre-2022

Resumen:

Este artículo de revisión bibliográfica basado en la búsqueda de artículos, fue realizado con la finalidad de reconocer las estructuras anatómicas del piso de la boca y los elementos que la constituyen, así como los hallazgos que pudieran ser relevantes. El piso de la boca es una región impar que se encuentra por debajo de la lengua dentro de la cavidad oral, su estudio es esencial para el odontólogo puesto que existen ciertas afecciones que pueden involucrar esta zona, tales como; obstrucciones del conducto submandibular, lesiones quísticas, tumorales, etc.; los mismos que pueden causar problemas severos, de no ser diagnosticados a tiempo, además, complicaciones como la anestesia dental insuficiente durante ciertos procedimientos pueden deberse a la presencia de comunicaciones nerviosas accesorias, por lo tanto, conocer la anatomía compleja de esta región es fundamental.

Metodología: Se realizó una búsqueda en las bases digitales en PubMed, Science Direct, Scopus y Google académico, seleccionando aquellos artículos que hayan sido realizados en humanos adultos y que estén orientados a la descripción morfológica de los elementos del piso de la boca.

Resultados: De un total de 107 artículos y tras un análisis metódico, aplicando los criterios de inclusión y exclusión, se eligieron finalmente 25 artículos para ser analizados y 2 libros de anatomía humana. Conclusiones: El conocimiento profundo de la anatomía de las estructuras que conforman el piso de la boca es de vital importancia para todos los profesionales que realizan procedimientos en la cavidad bucal.

Palabras claves: Piso de boca. Nervio Lingual. Glándula sublingual y submaxilar.

Abstract:

This bibliographic review article based on the search for articles was carried out with the purpose of recognizing the anatomical structures of the floor of the mouth and the elements that constitute it, as well as the findings that could be relevant. The floor of the mouth is an odd region that is found below the tongue within the oral cavity, its study is essential for the dentist since there are certain conditions that can involve this area, such as; obstructions of the submandibular duct, cystic lesions, tumors, etc.; the same ones that can cause severe problems, if not diagnosed in time, in addition, complications such as insufficient dental anesthesia during certain procedures can be due to the presence of accessory nerve communications, therefore, knowing the complex anatomy of this region is essential.

Methodology: A search was carried out in the digital databases in PubMed, Science Direct, Scopus and Academic Google, selecting those articles that have been carried out in adult humans and that are oriented to the morphological description of the elements of the floor of the mouth.

Results: From a total of 107 articles and after a methodical analysis, applying the inclusion and exclusion criteria, 25 articles were finally chosen to be analyzed and 2 books on human anatomy. **Conclusions:** The deep knowledge of the anatomy of the structures that make up the floor of the mouth is of vital importance for all professionals who perform procedures in the oral cavity.

Keywords: Floor of the Mouth. Lingual Nerve. Sublingual and submaxillary gland.

Cláusula de licencia y autorización para publicación en el Repositorio Institucional

Maritza Alexandra Esparza Quizhpi, en calidad de autor/a y titular de los derechos morales y patrimoniales del trabajo de titulación "Anatomical characterization of the floor of the mouth: A review of the literature", de conformidad con el Art. 114 del CÓDIGO ORGÁNICO DE LA ECONOMÍA SOCIAL DE LOS CONOCIMIENTOS, CREATIVIDAD E INNOVACIÓN reconozco a favor de la Universidad de Cuenca una licencia gratuita, intransferible y no exclusiva para el uso no comercial de la obra, con fines estrictamente académicos.

Asimismo, autorizo a la Universidad de Cuenca para que realice la publicación de este trabajo de titulación en el repositorio institucional, de conformidad a lo dispuesto en el Art. 144 de la Ley Orgánica de Educación Superior.

Cuenca, 20 septiembre-2022



Maritza Alexandra Esparza Quizhpi

C.I: 0350063970

Cláusula de licencia y autorización para publicación en el Repositorio Institucional

Karla Teresita Segovia Sigüenza, en calidad de autor/a y titular de los derechos morales y patrimoniales del trabajo de titulación "Anatomical characterization of the floor of the mouth: A review of the literature", de conformidad con el Art. 114 del CÓDIGO ORGÁNICO DE LA ECONOMÍA SOCIAL DE LOS CONOCIMIENTOS, CREATIVIDAD E INNOVACIÓN reconozco a favor de la Universidad de Cuenca una licencia gratuita, intransferible y no exclusiva para el uso no comercial de la obra, con fines estrictamente académicos.

Asimismo, autorizo a la Universidad de Cuenca para que realice la publicación de este trabajo de titulación en el repositorio institucional, de conformidad a lo dispuesto en el Art. 144 de la Ley Orgánica de Educación Superior.

Cuenca, 20 septiembre-2022



Karla Teresita Segovia Sigüenza

C.I: 0105410781

Cláusula de Propiedad Intelectual

Maritza Alexandra Esparza Quizhpi, autor/a del trabajo de titulación "Anatomical characterization of the floor of the mouth: A review of the literature", certifico que todas las ideas, opiniones y contenidos expuestos en la presente investigación son de exclusiva responsabilidad de su autor/a.

Cuenca, 20 septiembre-2022



Maritza Alexandra Esparza Quizhpi

C.I: 0350063970

Cláusula de Propiedad Intelectual

Karla Teresita Segovia Sigüenza, autor/a del trabajo de titulación "Anatomical characterization of the floor of the mouth: A review of the literature", certifico que todas las ideas, opiniones y contenidos expuestos en la presente investigación son de exclusiva responsabilidad de su autor/a.

Cuenca, 20 septiembre-2022



Karla Teresita Segovia Sigüenza

C.I: 0105410781

Introduction

In the diagnostic process of a patient, one of the elements of indisputable importance is the physical examination, and among the areas that can provide more local signs, the oral cavity stands out because there is no other area of the human anatomy that presents as many variables as this one, this makes the systematization of the examination fundamental to provide the available and necessary information [1,2]. Given the number of pathologies that can cause symptoms or signs in the structures that make up the oral cavity, their examination should be part of the arsenal of any specialist, the key to physical examination is to be methodical and systematic. [1,3].

The floor of the mouth, constituted by soft tissues and lacking bony reference planes, represents one of the most delicate regions of the oral cavity. It is actually a space containing the sublingual and submandibular glands, submandibular (Wharton's) and sublingual (Rivinus) gland excretory duct, as well as very important vascular and nervous elements. The anatomical planes are more difficult to identify, therefore, a very precise knowledge of the local anatomy is indispensable [1,2].

Various pathologic processes can involve the floor of the mouth such as cystic lesions, inflammatory processes, submandibular duct obstructions, vascular malformations, neoplastic lesions and pseudotumors. [2,6]. Some lesions arising in superficial tissues such as the buccal mucosa can be easily diagnosed on physical examination. However, computed tomography, magnetic resonance imaging or ultrasonography may be necessary and mostly reliable to evaluate lesions found in deeper anatomic structures. In such cases, knowledge of the complex muscular, vascular, glandular, ductal and neural anatomy of the region is important for accurate diagnosis and treatment planning. Familiarity with radiologic imaging appearances of the floor of the mouth and recognition of muscular anatomic landmarks are especially helpful in localizing disease within this region [4,6].

Objective

The objective of this article is to characterize topographically the anatomy of the floor of the mouth, as well as the findings that could be relevant.

Materials and methods

The search was performed in general and specialized anatomy articles and books dealing with the anatomy of the floor of the mouth, written in Spanish and English. In order to collect current data from the literature, articles published between 2000-2021 and books published between 2005-2008 were included.

An electronic literature search was carried out in the following digital databases: PubMed (Medline), Science Direct, Scopus and Google Scholar (SciELO). The search interaction was performed with the help of Boolean operators, combining the keywords: "Oral cavity", "Floor of the Mouth anatomy", "Salivary gland", "Submandibular gland", "Sublingual gland", "Sublingual and submandibular spaces", "Lingual and hypoglossal nerves". The search strategy used the Boolean operators "AND" and "OR" and added to the search if the terms appeared in at least: "Title", "Abstract", "Keywords" and "MeSH terms".

For the eligibility of the studies, the following inclusion criteria were applied: articles published between 2000-2021, scientific articles referring to descriptive observational studies, systematic reviews, clinical cases and literature reviews published between the years 2000-2021, scientific articles referring to descriptive observational studies, systematic reviews, clinical cases and literature reviews that were performed in adult humans and that were oriented to the morphological description of the elements of the floor of the mouth. Exclusion criteria were articles that did not have the full text available, letters to the editor and expert opinion articles.

A three-stage process was followed for the selection of studies. In the first stage, titles, abstracts and duplicate references were examined by the authors and excluded. In the second stage, the same researchers eliminated articles that were not related to the research topic. And in the third stage, documents that had full text as well as books that provided the required information were selected. Characteristics of the studies were observed as diagnostic criteria that made it possible to take advantage of them and use them in this article.

Results

In the electronic search of this literature review, a total of 107 articles referring to the topic were identified, which, after the analysis of the titles, abstracts and duplicate references, 56 studies were obtained, which after a filtering search of articles which had to include the full text, be published between the years 2000-2021 and that are oriented to the anatomical description of the elements that are part of the floor of the mouth. For this research, 32 results were initially determined, 29 full texts and 3 abstracts. After applying the inclusion and exclusion criteria, a final filtering of the content led to the final selection of 25 articles to be analyzed and 2 books of human anatomy published between 2005-2008, since these books have been used and applied by the doctors-teachers of the Faculty of Dentistry of the University of Cuenca who teach this content according to the established syllabus.

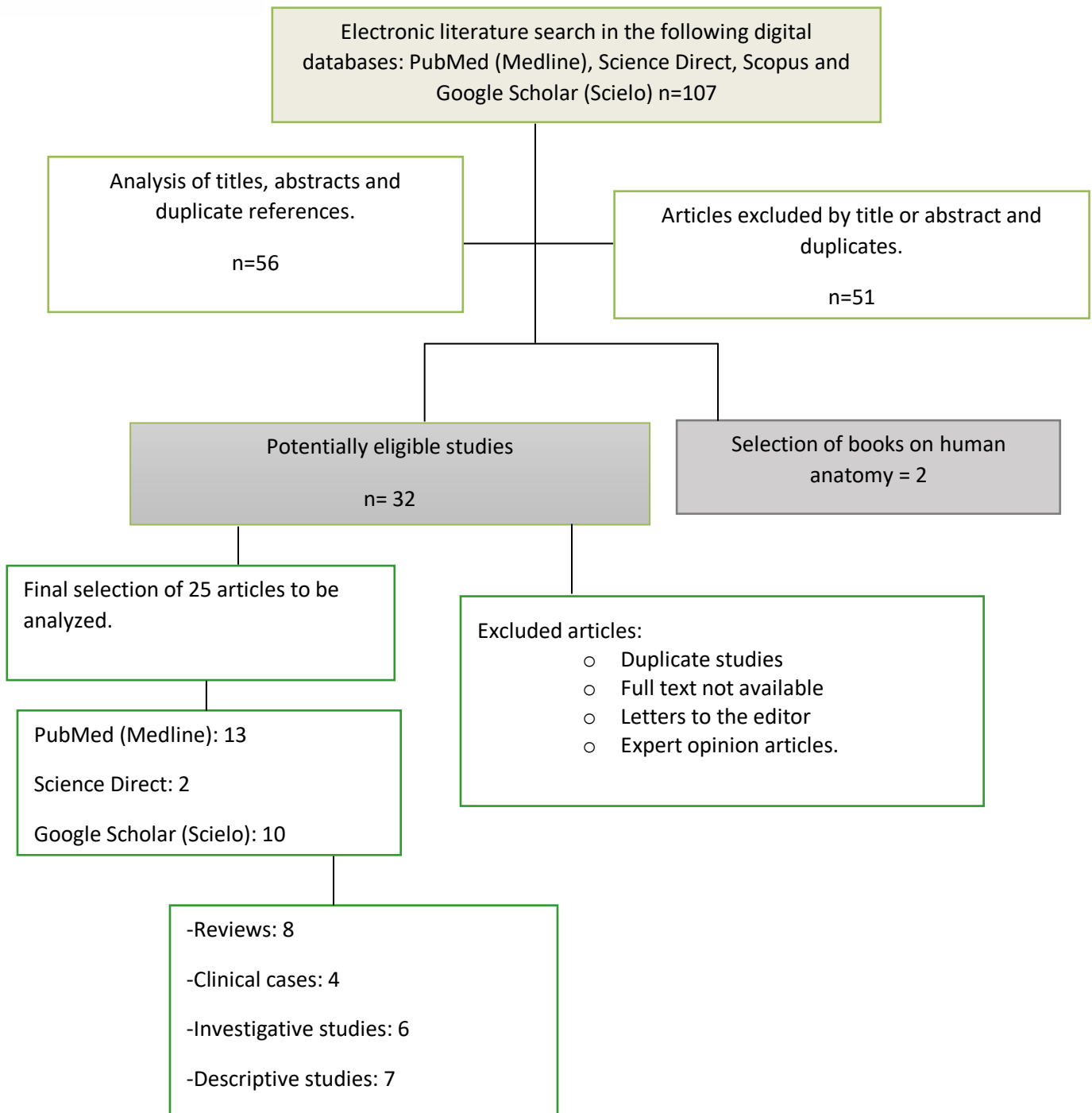


Figura 1 Search scheme for the selection of articles.

Discussion

According to Bouchet the floor of the mouth is an odd region that has the shape of a horseshoe, it is mainly constituted by soft tissues in which a mucosal, submucosal and muscular layer can be distinguished [4]. However, Sarah defines the floor of the mouth for surgical planning purposes as the space between the mucosal surface

and the sling of the mylohyoid muscle and comprises both structures [2]. In addition, a simpler definition can be used as described by Romero in which he states that the floor of the mouth is the part of the oral cavity below the tongue [7].

Regarding its limits, Camponiani mentions that the floor of the mouth is limited upwards by the buccal mucosa, below by the mylohyoid muscle, forwards and outwards by the internal face of the body of the mandible above the mylohyoid line, and backwards and inwards by the genioglossus, hyoglossus and inferior lingual muscles [4]. There are no other bibliographic references that indicate discrepancies between the limitation of this region, as well as its anatomical components.

In the muscular component, Chiapasco describes that the mylohyoid muscles examined by MRI in an axial section are born in the mylohyoid ridge of the internal face of the mandible, it extends; anteriorly, from the symphysis of the mandible, posteriorly; to the last molar [4]. Rouviere in the description of this muscle mentions three types of fibers, the posterior ones that run downwards to insert in the body of the hyoid, inferiorly to the insertion of the geniohyoid muscle. The anterior and middle fibers insert with those of the opposite side in the medial tendinous raphe and run from the mandibular symphysis to the hyoid. The two mylohyoid muscles together form a muscular girdle where the geniohyoid muscles and tongue rest. On the sides are the sublingual glands [5].

On the other hand, Sarah agrees on the extension of the muscle from the mandibular symphysis to the last molar tooth backwards and the insertion in the anterior face of the hyoid bone, without specifying the type of fibers it has and their direction [2]. Another important aspect described by Romero and Morikage is that the mylohyoid muscle separates the floor of the mouth from the right and left submandibular spaces and the submental space from the midline [7,9].

Another muscle that constitutes the floor of the mouth is the genioglossus muscle. White refers that the genioglossus muscle is fan-shaped and in relation to the lateral aspect of the lingual septum, it is located in the midline above the geniohyoid separating the sublingual glands. It extends from the superior geniculate processes to the superior border of the hyoid bone to the tongue. Below these we find the geniohyoid muscles that go from the inferior geniculate processes to the anterior aspect of the body of the hyoid bone [4]. Okabe attributes the function of the genioglossus muscle as a pharyngeal dilator, which is why it is supposed to play an important role in obstructive sleep apnea syndrome [10].

There are other muscles that are also related to the floor of the mouth, but their description based on the articles included in this study is not entirely detailed. Hatnakir and Tan indicate that in a coronal view the superior lingual muscle is

observed, which together with the genioglossus and geniohyoid muscles form the lingual septum, thus separating two spaces called sublingual cells, the hyoglossus is also seen bilaterally and below it is the mylohyoid muscle already described [4]. Santana also agrees that the genioglossus and geniohyoid muscles are at the root of the tongue, and the hyoglossus muscle is in the sublingual space [7].

Within the region of the floor of the mouth are the major salivary glands. Atkinson gave a very complete description of the submandibular glands and the sublingual glands. The submandibular gland is the second largest major salivary gland, weighing approximately 7 to 8 g which is half the weight of the parotid gland [11,12]. It is located in the submaxillary cell formed by the submaxillary fossa of the lower jaw, between the anterior and posterior bellies of the digastric muscle and along the inferior surface of the mylohyoid muscle. Posteriorly, the submandibular gland is separated from the parotid gland by the stylomandibular ligament. The posterior aspect of the submandibular gland forms a C-shaped structure around the dorsal free margin of the mylohyoid muscle, which divides the submandibular gland into superficial and deep lobes. The submandibular gland is encapsulated and covered by the superficial layer of the deep cervical fascia [11]. Sarah and Atkinson agree on the course of the submandibular duct (Wharton's duct) which drains the submandibular gland, exits the medial surface of the gland in the posterior sublingual space and runs under the floor of the mouth between the mylohyoid (lateral) and hyoglossus (medial) muscles, before emptying into the anterior floor of the mouth under the tongue at the sublingual caruncle, located lateral to the lingual frenulum [2,11]. But Atkinson adds that the lumen of Wharton's duct is larger than the papilla, and it is common for a sialolith or calculus to develop within the duct leading to obstruction of the duct [11].

Rhodes describes the sublingual gland as being olive-shaped, being the smallest with a size of 3 cm long and 5 to 7 cm wide and weighing less than 3 g [12]. It is located along the floor of the mouth between the mandible, the mylohyoid muscle and the root muscles of the tongue [4,11]. Atkinson describes that the sublingual gland has no true fascial capsule and lacks a dominant duct, instead it is drained by multiple small ducts called the ducts of Rivinus. However, they add and agree that there is some anatomic variation, and on occasion multiple sublingual ducts can merge to form the common Bartholin's duct, which usually empties into the main submandibular duct [11]. Patel mentions one of the pathologies in the sublingual space is the ranula, considered to be a post inflammatory or post traumatic sequela of glandular obstruction, is a mucous retention cyst arising from the sublingual or minor salivary glands. As the cystic lesion enlarges, it may "break" through the

confines of the sublingual space and extend into the submandibular space through the posterior free edge of the mylohyoid muscle or mylohyoid grommet [8].

In the floor of the oral cavity there are 2 significant nerves, which should be taken into consideration when evaluating this region; the lingual nerve and the hypoglossal nerve. Located within the infratemporal fossa we can appreciate the inferior alveolar and lingual nerves, both sensory and terminal branches of the mandibular nerve [13].

The inferior alveolar nerve originates deep to the lateral pterygoid muscle and descends into the fossa on the surface of the medial pterygoid muscle. Once it enters the mandible, the inferior alveolar nerve passes through the mandibular canal, which runs beneath the roots of the mandibular teeth, and carries sensory information from the mandibular molars, the mandibular second premolar, and the associated labial gingiva [13,14].

Similarly, the lingual nerve is one of the two terminal branches of the posterior division of the mandibular nerve. This nerve sometimes communicates with the inferior alveolar, auriculotemporal, or mylohyoid nerves [15]. Al-Amery [15], Dias [16], Meneses [17], have previously reported existing connections between the inferior alveolar and lingual nerves, and other branches of the mandibular nerve, Erdogmus [18] supports these investigations by explaining that these accessory communications may be involved in insufficient dental anesthesia due to the potential for collateral transmission of nerve impulses. The lingual nerve descends through the infratemporal fossa [18,19] and passes between the tensor veli palatini and lateral pterygoid muscles to finally enter the oral cavity [20], carrying general sensation of the anterior two-thirds of the tongue, the mucosa lining the floor of the oral cavity, and lingual gingivae associated with the mandibular teeth [13,15,17,20]. High in the infratemporal fossa, the lingual nerve is attached to the tympanic cord (branch of the facial nerve, cranial nerve VII), and therefore, also carries taste from the anterior two thirds of the tongue [15,21], secretomotor innervation for submandibular and sublingual glands [16] therefore, in the path of the lingual nerve a parasympathetic autonomic ganglion corresponding to the submandibular ganglion can be seen [17].

In general, the authors agree that the nerve travels along the periosteum on the medial surface of the body of the mandible to lie opposite the posterior root of the lower third molar [18,19]; here, it is covered only by the gingival mucoperiosteum [17], which is closely attached to the lingual plate of the mandible for a distance of 13 to 15 mm according to Dias [16] and 28.17 mm according to Al-Amery [15]. Studies have revealed that approximately 20 to 62% of the time, the lingual nerve is in contact with the lingual cortical plate [15]. In addition, it can be located above or

within the crest of the bone (4.6% and 21% of cases) [20, 22]. The least common site is the retromolar pad region, observed in 0.15 and 1.5% of cases [22]. When the lingual nerve is not in contact with the lingual plate, it is usually located within 2.28-16.8 mm below the alveolar ridge and 0.57-7.10 mm medial to the lingual plate [20]. Likewise, Trost found that the lingual nerve can be very close to the periosteum with an average horizontal distance of only 1.9 mm [23]. The shortest average distance between the lingual nerve and the retromolar region was 4.45-8.62 mm [18]. Also, the average distance from the mesial and distal portion of the mandibular third molar area to the lingual nerve has been reported to be 9.5 mm and 15.5 mm, respectively [19].

According to Dias [16], studies suggest that the actual distance between the lingual nerve and the mandible oscillates significantly, such that the approximate horizontal distances measured from the lingual lamina range from 0.59 mm to 4.19 mm; conversely, the vertical distances to the lingual ridge range from 0.52 mm to 15.5 mm below.

The lingual nerve can also innervate the gingiva, the lingual periosteum, and the overlying mucosa medially, via a branch to the lingual gingival tissue, which extends horizontally from the medial mandibular cortex at the level of the retromolar pad to mesial of the lower first molars and second premolars [15].

A little further back, the hypoglossal nerve, strictly motor, emerges through the base of the skull at the level of the hypoglossal canal [23] or anterior condyle foramen [12, 24], because it is located precisely anterolateral to the condyle of the occipital bone [23], the hypoglossal nerve descends through the neck, crosses laterally the carotid arteries and then projects to the floor of the mouth together with the lingual vessels, lingual artery and lingual vein [12, 24]. Also in its route at the neck level it receives a communicating branch of the first cervical nerve, and in a certain trajectory, it will conduct certain axons of the cervical branch of C1, which will be directed to the thyrohyoid muscle and motor innervation to the geniohyoid [20, 25, 26]. Therefore, and in a certain pathway of the hypoglossal nerve it will carry its own fibers for the tongue muscles but it will also carry certain axons from the cervical branch of C1 [20]; Lee SH [23] explains that we cannot make the mistake of saying that the geniohyoid muscle is innervated by the hypoglossal nerve because apparently it is, however, the branch that reaches the geniohyoid muscle comes from the hypoglossal nerve, but the axons are not from the XII pair, but from the ventral branch of the first cervical nerve.

Finally, the irrigation of the floor of the mouth depends initially on the lingual artery [26], this artery arises as the second anterior collateral of the external carotid artery,

above the superior thyroid and below the facial artery, having a great variation in its location that the clinician must take into account [15]. It has several concavities that allow it great mobility along with the movement of the tongue and during its trajectory it irrigates several structures of the floor of the mouth [20]. The lingual artery accompanies the hypoglossal nerve and projects to the floor of the mouth, supplying these structures and the tongue muscles [27]. For its part, the lingual vein drains the internal jugular vein forming a common trunk with the facial vein, the superior thyrohyoid vein [20] and according to Delaey [24] also includes the ascending pharyngeal vein which is known as the thyroinguopharyngopharyngeal venous trunk tributary to the internal jugular vein [20, 27].

Conclusions

Based on the information obtained, the anatomical description in the literature of the structures that make up the floor of the mouth is limited in terms of innervation, definition, location and anatomical structures such as muscles and major salivary glands. Although the anatomy has not changed considerably over the years, it is necessary to understand the anatomical variations so that the dentist can adopt alternative anesthetic techniques if required. Physical examination can be used to evaluate superficial lesions in this region; however, computed tomography, magnetic resonance imaging or ultrasound are more effective for evaluating deeper lesions.

Acknowledgments

The authors would like to thank their tutor, Dr. David Manuel Pineda Álvarez, and their family members who have supported them throughout their university education.

Conflict of Interest

The authors have declared that there is no conflict of interest.

Bibliografía

1. Berner JE, Will P, Loubies R, Vidal P. Examen físico de la cavidad oral. *Med Cutan Iber Lat Am.* [Internet]. 2016;44(3):167–170. Disponible en: <https://www.medigraphic.com/pdfs/cutanea/mc-2016/mc163c.pdf>

2. La'Porte SJ, Juttla JK, Lingam RK. Imaging the Floor of the Mouth and the Mouth and the Sublingual Space. *RadioGraphics*. [Internet]. 2011;31(5):1215–1230. Disponible en: <https://pubs.rsna.org/doi/pdf/10.1148/rg.315105062>
3. Bell FE, Neuffer FH, Haddad TR, Epps JC, Kozik ME, Warren BC. Active Learning of the Floor of Mouth Anatomy with Ultrasound. *Anat Sci Educ*. [Internet]. 2019;12(3):310–316. Disponible en: <https://sci-hub.se/10.1002/ase.1839>
4. Quispe Huarcaya M, Sovero Gaspar A, Gutierrez Ventura F. Evaluación anatómica del piso de boca mediante resonancia magnética. *Rev Estomatol Hered*. [Internet]. 2015;25(4):309–317. Disponible en: <http://www.scielo.org.pe/pdf/reh/v25n4/a09v25n4.pdf>
5. Rouviere H, Delmas A. Anatomía Humana. Descriptiva, Topográfica y Funcional. Undécima edición. Barcelona-España: MASSON;2005. p. 192-193.
6. Truong MT, Nadershah M, Langmore SE, Kuno H, Sakai O, Salama A, et al. Advanced Floor of Mouth Cancer. *Oral, Head and Neck Oncology and Reconstructive Surgery*. [Internet]. 2018;22: 428-457. Disponible en: <https://sci-hub.se/http://dx.doi.org/10.1016/B978-0-323-26568-3.00022-1>
7. Romero Díaz KR, Sovero Gaspar A, Gutierrez Ventura F. Músculos del piso de boca en TEM vs. IRM. *Rev Estomatol Hered*. [Internet]. 2019;29(2):158-165. Disponible en: <http://www.scielo.org.pe/pdf/reh/v29n2/a08v29n2.pdf>
8. Patel S, Bhatt AA. Imaging of the sublingual and submandibular spaces. *Insights into Imaging*. [Internet]. 2018;9:391–401. Disponible en: <https://sci-hub.se/10.1007/s13244-018-0615-4>
9. Morikage N, Hamada T, Usami A, Takada S. Topographical relationship between positions of lingual foramina and attachment of mylohyoid muscle in mental region. *Surg Radiol Anat*. [Internet]. 2017;39(7):735-739. Disponible en: <https://pubmed.ncbi.nlm.nih.gov/28078367/>
10. Mareque Bueno J, Martínez Fuster X, González Lagunas J, Bassas C, Raspall Martin G. Avance geniogloso en el tratamiento del síndrome de apnea obstructiva del sueño. *Rev Esp Cirug Oral y Maxilofac*. [Internet]. 2005;25(3):161–166. Disponible en: https://scielo.isciii.es/scielo.php?script=sci_arttext&pid=S1130-05582005000300008

11. Atkinson C, Fuller j, Huang B. Cross-Sectional Imaging Techniques and Normal Anatomy of the Salivary Glands. *Neuroimaging Clinics of North America*. [Internet]. 2018;28(2):137-158. Disponible en: <https://sci-hub.se/10.1016/j.nic.2018.01.001>
12. Rodas Abad E. Anatomía Humana para Odontología. Tercera edición. Cuenca-Ecuador: Universidad de Cuenca; 2008. p. 216-218.
13. Wolf KT, Brokaw EJ, Bell A, Joy A. Variant inferior alveolar nerves and implications for local anesthesia. *Anesth Prog*. [Internet]. 2016;63(2):84–90. Disponible en: <https://sci-hub.se/10.2344/0003-3006-63.2.84>
14. Suazo Galdames I, Zavando Matamala D, Cantín López M. Canal mandibular accesorio: Análisis de su prevalencia y aspecto imagenológico. *Av Odontoestomatol*. [Internet]. 2011;27(2):85–90. Disponible en: https://scielo.isciii.es/scielo.php?script=sci_abstract&pid=S0213-12852011000200004
15. Al-Amery SM, Nambiar P, Naidu M, Ngeow WC. Variation in lingual nerve course: A human cadaveric study. *PLoS One*. [Internet]. 2016;11(9):1–20. Disponible en: <https://www.ncbi.nlm.nih.gov/pmc/articles/PMC5035068/pdf/pone.0162773.pdf>
16. Dias GJ, De Silva RK, Shah T, Sim E, Song N, Colombage S, et al. Multivariate assessment of site of lingual nerve. *Br J Oral Maxillofac Surg* [Internet]. 2015;53(4):347–51. Available from: <http://dx.doi.org/10.1016/j.bjoms.2015.01.011>
17. Meneses MB, de Carvalho Leite Leal Nunes CM, de Almeida Lopes MC. Anatomical Relationship of Lingual Nerve to the Region of Mandibular Third Molar. *J Oral Maxillofac Res*. [Internet]. 2013;4(4):1–7. Disponible en: <https://www.ncbi.nlm.nih.gov/pmc/articles/PMC3904728/pdf/jomr-04-e2.pdf>
18. Erdogmus S, Govsa F, Celik S. Anatomic position of the lingual nerve in the mandibular third molar region as potential risk factors for nerve palsy. *J Craniofac Surg*. [Internet]. 2008;19(1):264–70. Disponible en: <https://pubmed.ncbi.nlm.nih.gov/18216699/>
19. Kim SY, Hu KS, Chung IH, Lee EW, Kim HJ. Topographic anatomy of the lingual nerve and variations in communication pattern of the mandibular nerve branches. *Surg Radiol Anat*. [Internet] 2004;26(2):128–35. Disponible en: <https://pubmed.ncbi.nlm.nih.gov/14586562/>
20. Benninger B, Kloenne J, Horn JL. Clinical anatomy of the lingual nerve and identification with ultrasonography. *Br J Oral Maxillofac Surg*. [Internet]. 2013;51(6):541–4. Available from: <http://dx.doi.org/10.1016/j.bjoms.2012.10.014>

21. Sittitavornwong S, Babston M, Denson D, Zehren S, Friend J. Clinical Anatomy of the Lingual Nerve: A Review. *J Oral Maxillofac Surg* [Internet]. 2017;75(5):926.e1-926.e9. Available from: <http://dx.doi.org/10.1016/j.joms.2017.01.009>
22. Behnia H, Kheradvar A, Shahrokhi M. An anatomic study of the lingual nerve in the third molar region. *J Oral Maxillofac Surg*. [Internet]. 2000;58(6):649–51. Disponible en: <https://pubmed.ncbi.nlm.nih.gov/10847287/>
23. Lee SH, Lee ES, Yoon CH, Shin H, Lee CH. Collet-Sicard syndrome with hypoglossal nerve schwannoma: A case report. *Ann Rehabil Med*. [Internet]. 2017;41(6):1100–4. Disponible en: <https://www.ncbi.nlm.nih.gov/pmc/articles/PMC5773432/pdf/arm-41-1100.pdf>
24. Delaey P, Duisit J, Behets C, Duprez T, Gianello P, Lengelé B. Specific branches of hypoglossal nerve to genioglossus muscle as a potential target of selective neurostimulation in obstructive sleep apnea: anatomical and morphometric study. *Surg Radiol Anat*. [Internet]. 2017;39(5):507–15. Disponible en: https://www.ncbi.nlm.nih.gov/pmc/articles/PMC5406428/pdf/276_2016_Article_1778.pdf
25. Pascual MV, Gallego Y, Vázquez D, et al. Etiología de la parálisis del nervio hipogloso. Revisión sistemática: Idiopathic Hypoglossal Nerve Palsy Etiology. Systematic Review. [Internet]. 2021;47–53. Disponible en: <https://scielo.isciii.es/pdf/orl/v12n1/2444-7986-orl-12-01-47.pdf>
26. Rivera C. Consideraciones anatómicas y clínicas del nervio hipogloso: revisión de la literatura. *Univ Médica*. [Internet]. 2015;56(3):323–40. Disponible en: <https://www.redalyc.org/pdf/2310/231042610008.pdf>
27. Pan M, Ma T, Mao J, Qin X, Li B. Clinical application of foci contralateral facial artery myomucosal flap for tongue defect repair. *Plast Reconstr Surg - Glob Open*. [Internet]. 2018;6(2):1–4. Disponible en: <https://www.ncbi.nlm.nih.gov/pmc/articles/PMC5865938/pdf/gox-6-e1669.pdf>