Facultad de Odontología

Carrera de Odontología

“Oral mucosal melanoma: a case report and literature review”

Trabajo de titulación previo a la obtención del título de: Odontología

Modalidad: Artículo Académico.

Autora:

Daniela Salomé Chamba León

CI: 1104600661

Correo electrónico: danielachamba97@gmail.com

Autor:

Pablo Rodrigo Ruiz Maila

CI: 1722527254

Correo electrónico: pr18.ruiz@gmail.com

Director:

Diego Mauricio Bravo Calderón

CI: 0104514237

Cuenca, Ecuador

02-junio-2022

Resumen: El melanoma de la mucosa oral es un tumor maligno inusual y agresivo que afecta principalmente al paladar de hombres de entre 50 y 60 años. Presentamos una revisión bibliográfica centrada en la etiopatogenia y las características clínico-patológicas de esta entidad. Además, reportamos un caso raro de melanoma de la mucosa oral que surgió en la mejilla izquierda de un hombre de 60 años. La tomografía computarizada reveló la infiltración del tumor a otras estructuras anatómicas, incluido el seno maxilar, el hueso cigomático y los procesos pterigoideos. En base a su extensión, la lesión se consideró inoperable y se propuso tratamiento con radioterapia conformada tridimensional pero el paciente solo asistió a la primera sesión y falleció por progresión del cáncer 6 meses después del diagnóstico. Este trabajo refuerza la importancia de la inclusión de este tumor maligno en el diagnóstico diferencial de las lesiones pigmentadas de la mucosa oral.

Palabras claves: Melanoma mucoso. Lesión pigmentada. Mucosa oral. Cáncer oral. Reporte de caso.

Abstract: Oral mucosal melanoma is an unusual and aggressive malignant tumor that mainly affects the palate of men aged between 50 and 60 years. We present a literature review focusing on the etiopathogenesis and the clinicopathologic features of this entity. In addition, we reported a rare case of an oral mucosal melanoma arising in the left cheek of a 60-year-old man. Computed tomography scan revealed infiltration of the tumor to other anatomic structures including the maxillary sinus, the zygomatic bone and the pterygoid processes. Based on its extension, the lesion was considered inoperable and treatment with three-dimensional conformal radiation therapy was proposed but the patient only attended to the first session and died from cancer progression 6 months after the diagnosis. This paper reinforces the importance of inclusion of this malignant tumor in the differential diagnosis of pigmented lesions of the oral mucosa.

Keywords: Mucosal melanoma. Pigmented lesion. Oral mucosa. Oral cancer. Case report.

Cláusula de licencia y autorización para publicación en el Repositorio Institucional

Daniela Salomé Chamba León en calidad de autor y titular de los derechos morales y patrimoniales del trabajo de titulación “Oral mucosal melanoma: a case report and literature review”, de conformidad con el Art. 114 del CÓDIGO ORGÁNICO DE LA ECONOMÍA SOCIAL DE LOS CONOCIMIENTOS, CREATIVIDAD E INNOVACIÓN reconozco a favor de la Universidad de Cuenca una licencia gratuita, intransferible y no exclusiva para el uso no comercial de la obra, con fines estrictamente académicos.

Asimismo, autorizo a la Universidad de Cuenca para que realice la publicación de este trabajo de titulación en el repositorio institucional, de conformidad a lo dispuesto en el Art. 144 de la Ley Orgánica de Educación Superior.

Cuenca, 2 de junio de 2022

Daniela Salomé Chamba León

C.I: 1104600661

Cláusula de licencia y autorización para publicación en el Repositorio Institucional

Pablo Rodrigo Ruiz Maila en calidad de autor y titular de los derechos morales y patrimoniales del trabajo de titulación “Oral mucosal melanoma: a case report and literature review”, de conformidad con el Art. 114 del CÓDIGO ORGÁNICO DE LA ECONOMÍA SOCIAL DE LOS CONOCIMIENTOS, CREATIVIDAD E INNOVACIÓN reconozco a favor de la Universidad de Cuenca una licencia gratuita, intransferible y no exclusiva para el uso no comercial de la obra, con fines estrictamente académicos.

Asimismo, autorizo a la Universidad de Cuenca para que realice la publicación de este trabajo de titulación en el repositorio institucional, de conformidad a lo dispuesto en el Art. 144 de la Ley Orgánica de Educación Superior.

Cuenca, 2 de junio de 2022

Pablo Rodrigo Ruiz Maila

C.I: 1722527254

Daniela Salomé Chamba León autora del trabajo de titulación “Oral mucosal melanoma: a case report and literature review”, certifico que todas las ideas, opiniones y contenidos expuestos en la presente investigación son de exclusiva responsabilidad de su autor.

Cueca, 2 de junio de 2022

Daniela Salomé Chamba León

C.I: 1104600661

Pablo Rodrigo Ruiz Maila autor del trabajo de titulación “Oral mucosal melanoma: a case report and literature review”, certifico que todas las ideas, opiniones y contenidos expuestos en la presente investigación son de exclusiva responsabilidad de su autor.

Cueca, 2 de junio de 2022

Pablo Rodrigo Ruiz Maila

C.I: 1722527254

INTRODUCTION

Oral mucosal melanoma (OMM) is a rare and highly aggressive malignant neoplasm that accounts for 0.5% of oral malignant tumors (Chandan, Shetty, & Deepa, 2020; Shen, Liu, Bao, Zhou, & Wang, 2011; Singh, Pandey, Singh, & Kudva, 2019; Smith et al., 2016; Sortino-Rachou, Cancela Mde, Voti, & Curado, 2009). The tumor is initially asymptomatic and clinically it is observed as a flat pigmented lesion of irregular contour or as an accelerated growth mass of light or dark brown, black, white or even the same color as the adjacent mucosa, therefore, in most cases it is overlooked during the clinical dental examination, which hinders its early diagnosis and worsens its prognosis (Lopez-Graniel, Ochoa-Carrillo, & Meneses-Garcia, 1999; Singh et al., 2019). The aim of this paper is to present a case of melanoma located in an unusual region of the oral mucosa and to review the clinicopathologic features of the lesion.

CASE REPORT

A 60-year-old male presented a burning sensation on the left buccal mucosa with an approximate evolution time of two months. His medical and family history were unremarkable. The intraoral clinical examination revealed a black enlargement of about 0.8cm in its largest diameter and that was interposed with the occlusion of the molars which were restored with amalgam, therefore, amalgam tattoo was formulated as the initial presumptive diagnosis. During surgical resection it was observed that the lesion extended deeply into the tissues and showed intense black color with positivity to the friction test with gauze (Fig. 1).

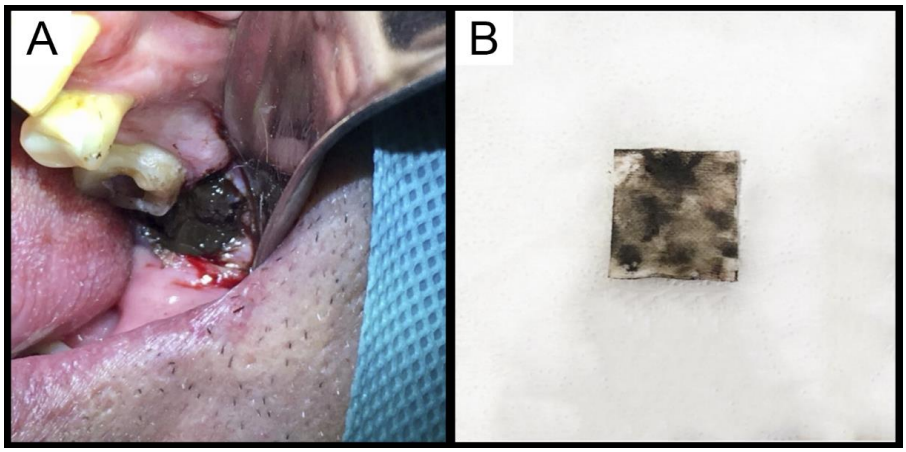

Fig. 1. Intraoperative photographs. **A**: Left buccal mucosa with intense black pigmentation. **B**: Positive gauze rub test.

An incisional biopsy was obtained by removing as much tissue as possible and oral mucosal melanoma was included in the clinical differential diagnosis. Histopathologic examination (Fig. 2) revealed, along the subepithelial connective tissue, several neoplastic melanocytes exhibiting epithelioid, plasmacytoid or spindle-shaped morphology, with hyperchromic nuclei, some binuclear and with vesicular chromatin. Additionally, infiltration of the skeletal striated muscle and abundant melanin located in the cytoplasm of the neoplastic cells or randomly arranged in the stroma, were observed. Based on the clinical and microscopic features, the definitive diagnosis established was oral mucosal melanoma and the patient was referred to a specialized cancer treatment center, where the diagnosis was confirmed and complementary tomographic studies were obtained.

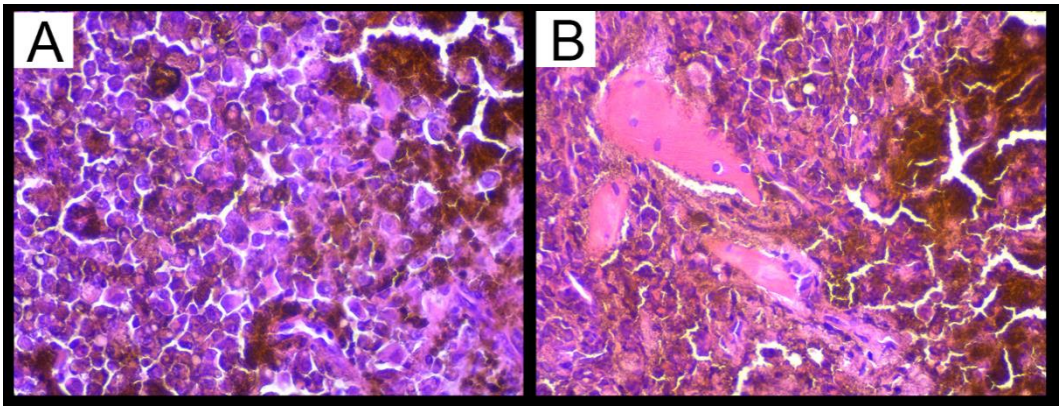

Fig. 2. Histopathologic findings. **A:** Polymorphic neoplastic cells with clear or pigmented cytoplasm, round or oval hyperchromatic nuclei, and prominent "*cherry red*" nucleoli. **B:** Tumor cells with nuclear pleomorphism that infiltrate the striated muscle tissue and with abundant presence of melanin dispersed between the cells.

In the computed tomography (CT) cross sections, a soft tissue mass of 50mm x 29mm of diameter was observed, which infiltrated the ipsilateral maxillary sinus, the zygomatic bone and the pterygoid processes (Fig. 3). No locoregional or distant metastasis were verified. Due to its extension, the lesion was considered inoperable and it was proposed a treatment based on three-dimensional conformal radiotherapy with a dose of 40Gy in 8 fractions; however, the patient attended only the first session and died 6 months after the diagnosis.

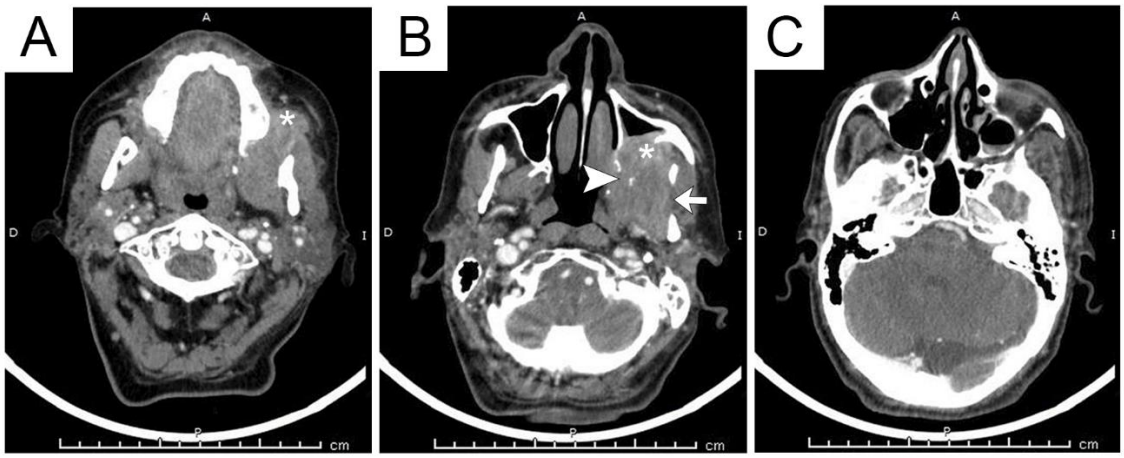

Fig. 3. Cranial Computed Axial Tomography **A**: Mass delimited in the left zygomatic space in proximity to the mandibular ramus and causing facial volume increase. **B**: Tumor extension towards the maxillary sinus and parapharyngeal space with destruction of the posterior wall of the maxillary sinus (asterisk), the pterygoid processes (arrow) and the mandibular ramus (arrowhead). **C**: Destruction of the left zygomatic arch.

DISCUSSION AND LITERATURE REVIEW

Mucosal melanomas (MM), including those of the head and neck as the OMM, are a type of cancer characterized by the proliferation of atypical melanocytes and the production of high amounts of melanin (Francisco et al., 2016; Shen et al., 2011). Specifically, OMM is more aggressive than their cutaneous counterparts, represents 0.2–8% of all melanomas, being that, a multicenter study verified that only 8% of it develops in hispanic patients, which implies that the rarity of the lesion in this geographic region can lead to underestimate it, and it may even go unnoticed in its early stages during routine clinical examination (Nenclares et al., 2020; Smith et al., 2016; Sortino-Rachou et al., 2009).

OMM is more prevalent in men with a male to female ratio of 1:0.78, is regularly found between the fifth and sixth decade of life and is most commonly located in the palate (34%), in the gingiva (8.8%), with only 4.38% of these lesions occurring in the buccal mucosa (Mikkelsen et al., 2016; Singh et al., 2019; Smith et al., 2016; Sortino-Rachou et al., 2009).

Clinically, the lesion is usually asymptomatic; moreover, symptomatology can be observed when prosthesis or tooth brushing produce ulceration or bleeding of the entity (Maymone et al., 2019; Singh et al., 2019). In addition, this neoplasm has various clinical manifestations, it can be flat or a mass of accelerated growth, and can exhibit the same color as the underlying mucosa (30% of the lesions) or more intense colors, such as brown, black, red or purple (Chandan et al., 2020; Deyhimi et al., 2017; Lopez-Graniel et al., 1999; Maymone et al., 2019; Singh et al., 2019; Smith et al., 2016; Sortino-Rachou et al., 2009). Thereby, the clinical differential diagnosis of OMM includes benign pigmented lesions (nevus, melanosis associated with smoking or drugs, amalgam tattoo, melanoacanthoma, melanotic macule, and vascular lesions), benign inflammatory lesions (epulis, peripheral giant cell granuloma and peripheral ossifying fibroma); and malignant pigmented lesions (Kaposi Sarcoma) (Deyhimi et al., 2017;

Smith et al., 2016). Here we reported a case of OMM arising from the buccal mucosa with a great extension to the neighboring tissues and, that based on its small size and proximity with amalgam restorations, was initially considered as a black benign pigmentation. Curiously, the scientific literature reveals that 57.7% of the clinicians list different benign diagnoses as their first impression of OMM (Smith et al., 2016).

The clinical differentiation of OMM from other pigmented entities of the oral mucosa can be assisted by the use of the gauze rub test, which is a simple, non-invasive and highly sensitive method that is considerate positive for OMM when the gauze is stained of black or dark brown after rubbing the surface of the lesion (Delgado Azanero & Mosqueda Taylor, 2003). According to Delgado and Mosqueda the black color acquired by the gauze is a consequence of the presence of malignant melanocytes laden with high amounts of melanin and the test is positive in 84.6% of the lesions with diagnosis of OMM confirmed by histopathology (Delgado Azanero & Mosqueda Taylor, 2003).

On the other hand, a negative result of the gauze rub test does not rule out the possibility of OMM (vertical growth pattern or melanocytic variant), especially when the lesion shows the parameters of the ABCDE rule for melanoma, criteria which, together, have a significant sensitivity and specificity (89.3% and 65.3%, respectively) in the detection of cutaneous melanomas (Hicks & Flaitz, 2000; Topic, Masic, Radovic, Lincender, & Muhic, 2017). In addition to ABCDE criteria, Šitum et al in Berislav, 2017, due to the complexity shown by mucosal melanomas, suggest the addition of 2 parameters, being: F - feeling (burning, pain or itching) and G - growth (increase in size) (Table I) (Topic et al., 2017).

Table I. ABCDEFG of mucosal melanoma (Topic et al., 2017).

A – Asymmetry: One half is different from the other half.
B – Border: An irregular, scalloped or ill-defined border.
C – Color: Varies from one area to another with shades from brown to black or sometimes white, blue or white.
D – Diameter: Melanomas are usually larger than 6 mm, but may be smaller.
E – Evolution: Skin lesion that looks different from the rest or is changing in shape, size or color.
F – Feeling: Of burning, pain or itching.
G – Growth: Increase in size.

As described in the present report, the burning sensation on the area and the pigmentation of the gauze suggested the presence of an OMM. Indepenly of the clinical parameters, the definitive diagnosis of OMM is established by histopathological examination (Deyhimi et al., 2017; Shen et al., 2011; Smith et al., 2016; Sortino-Rachou et al., 2009). Microscopic reports recognize that OMM has radial and/or rapid and early vertical growth, invading superficial tissues and infiltrating deeper tissues; therefore histopathologically, it can show three patterns: (a) *in situ* which is limited to the epithelium with proliferation of atypical melanocytes radially in the basal layer; (b) invasive in which the neoplasm has penetrated the underlying connective tissue with

nests of atypical melanocytes in the lamina propria by vertical growth; and (c) combined pattern which is typical in more advanced lesions (Deyhimi et al., 2017; Feller, Khammissa, & Lemmer, 2017).

Specifically, the malignant melanocytes can show different phenotypes (polyhedral, round, epithelioid, spindle-shaped or pleomorphic) and sizes (Barnes, 2000). They exhibit clear cytoplasm, round to oval nuclei, with one or more hyperchromic ("cherry red") or prominent nucleoli, and single cells can be found along the epithelium (*in situ*, invasive and combined pattern) or grouped in nests mainly below the interface (invasive and combined pattern), with or without the presence of seromucous glands (*in situ* pattern) and with intracellular melanin (Barnes, 2000; Coutinho-Camillo, Lourenço, & Soares, 2016). Occasionally, due to the histological diversity of the lesion, auxiliary immunohistochemical (IHC) markers are required to identify S100, Mart1/Melan-A, MITF and HMB45 proteins, which are determinants to confirm the diagnosis of OMM (Table II) (Coutinho-Camillo et al., 2016; Feller et al., 2017; Smith et al., 2016; Topic et al., 2017).

Table II. Inmunohistochemical profile of mucosal melanoma.

Protein/marker	Pattern of expression	Percentage of cases in which it is expressed	References
S100	Positive (less specific protein).	90-100%	Smith, 2016[4]. & Berislav, 2017[14].
Mart1/Melan-A	Positive (less specific protein).	82%	Busam, 2005 [28].
MITF	Positive (difuse).	50%	Morris 2008 [29].
HMB45	Positive.	95%	Smith, 2016 [4].
C-kit	Positive (high expression rates).	14%	Coutinho-Camillo, 2015 [18].
BRAF	Positive.	5%	Coutinho-Camillo, 2015 [18].
NRAS	Positive.	14%	Coutinho-Camillo, 2015 [18].

Tyrosinase	Positive.	92%	Busam, 2005 [28].
p53	Positive (accumulation).	58%	Coutinho-Camillo, 2015[18].
Cox-2	Positive.	92%	Souza, 2015 [23].

Regarding the etiology of the tumor, it is not fully clarified, in view of the fact that melanocytes may be present in the oral mucosa, especially in melanoderm people; and in these conditions the specific function of these cells in oral soft tissues is unknown (Chandan et al., 2020; Martín et al., 2014).

However, some authors correlate the genesis of the tumor with previous mucosal pigmentation, amalgam tattoos, or external factors such as poorly adapted dental prosthesis, smoking which fluctuates between 10-25% in a period of 5 years (Francisco et al., 2016; López et al., 2016; Mikkelsen et al., 2016; Rambhia, Stojanov, & Arbesman, 2019; Shen et al., 2011; Singh et al., 2019). In cutaneous melanoma, several mutations have been identified in BRAF, KIT, NRAS genes and in the COX-2 enzyme, most of them induced by UV radiation; however, the low frequency of OMM in association with its late diagnosis do not allow obtaining statistically significant results of mutations in mucosa that help to elucidate the etiology nor to conduct the early diagnosis and prevention of the disease (de Souza do Nascimento et al., 2016; Feller et al., 2017; Hsieh et al., 2017; Mikkelsen et al., 2016; Wong et al., 2019).

Staging is fundamental in order to plan the treatment and to determine the prognosis of the patients, thereby, the American Joint Committee on Cancer (AJCC) uses a staging system for cutaneous melanomas, which cannot be applied to their mucosal counterparts, because they, generally at the time of diagnosis, are in stage I which implies that the tumor has invaded nearby tissues in a small area without metastasis in lymph nodes or at a distance (primary localization of the disease) (Thompson, 2002). For this reason Prasad et al. stipulate that in primary mucosal melanomas without lymph node spread, it is necessary to take into consideration the histological pattern of invasion that was found to be a significant and independent predictor of survival of the patients (Table III) (Prasad, Patel, Huvos, Shah, & Busam, 2004; Thompson, 2002).

Table III. Staging for mucosal melanoma (Prasad, Patel, Huvos, Shah, & Busam, 2004).

Stage I	Primary disease location.
Level I	Mucosal melanoma *in situ.*
Level II	Invasion restricted to the lamina propria.
Level III	Melanoma with deep invasion of surrounding tissue, such as bone (in the oral mucosa), cartilage (in the larynx) or skeletal muscle.
Stage II	Primary disease with metastasis to cervical lymph nodes.
Stage III	Distant metastases.

The main treatment for OMM is radical resection of the lesion with safety margins of up to 2cm, and may include adjuvant treatments to improve the survival rate by up to 10%, such as: chemotherapy, radiotherapy, and immunotherapy (interleukin-2 and interferon- alpha) (Ashok, Damera, Ganesh, & Karri, 2020; Feller et al., 2017; Martín et al., 2014; Maymone et al., 2019). However, regardless of the therapy administered, the prognosis of OMM is poor with a very high propensity to relapse and a few long-term survivors (Francisco et al., 2016; López et al., 2016).

CONCLUSION

In conclusion, OMM is a rare and aggressive malignant neoplasm that should be considered by the professional when observing pigmented mucosal lesions during routine clinical examination, being useful, for the clinical differential diagnosis, the application of the ABCDEFG criteria in combination with the gauze rub test.

REFERENCES

Ashok, S., Damera, S., Ganesh, S., & Karri, R. (2020). Oral malignant melanoma. *J Oral Maxillofac Pathol, 24*, S82-S85.

Barnes, L. (2000). *Surgical pathology of the head and neck* (Vol. 1). New York: Informa Healthcare USA, Inc.

Chandan, S. N., Shetty, S. K., & Deepa, B. V. (2020). Primary Malignant Melanoma of Oral Mucosa - Report of Two Cases. *Contemp Clin Dent, 11*, 195-198. doi:10.4103/ccd.ccd_380_19

Coutinho-Camillo, C. M., Lourenço, S. V., & Soares, F. A. (2016). Head and neck: Primary oral mucosal melanoma. *Atlas Genet Cytogenet Oncol Haematol, 20*, 52-60.

de Souza do Nascimento, J., Carlos, R., Delgado-Azanero, W., Mosqueda Taylor, A., de Almeida, O. P., Romanach, M. J., & de Andrade, B. A. (2016). Immunohistochemical expression of cyclooxygenase-2 (COX-2) in oral nevi and melanoma. *J Oral Pathol Med, 45*, 440-443. doi:10.1111/jop.12385

Delgado Azanero, W. A., & Mosqueda Taylor, A. (2003). A practical method for clinical diagnosis of oral mucosal melanomas. *Med Oral, 8*, 348-352. Retrieved from https://www.ncbi.nlm.nih.gov/pubmed/14595259

Deyhimi, P., Razavi, S. M., Shahnaseri, S., Khalesi, S., Homayoni, S., & Tavakoli, P. (2017). Rare and extensive malignant melanoma of the oral cavity: report of two cases. *Journal of Dentistry, 18*, 227.

Feller, L., Khammissa, R. A. G., & Lemmer, J. (2017). A Review of the Aetiopathogenesis and Clinical and Histopathological Features of Oral Mucosal Melanoma. *ScientificWorldJournal, 2017*, 9189812. doi:10.1155/2017/9189812

Francisco, A. L., Furlan, M. V., Peresi, P. M., Nishimoto, I. N., Lourenco, S. V., Pinto, C. A., . . . Ikeda, M. K. (2016). Head and neck mucosal melanoma: clinicopathological analysis of 51 cases treated in a single cancer centre and review of the literature. *Int J Oral Maxillofac Surg, 45*, 135-140. doi:10.1016/j.ijom.2015.08.987

Hicks, M. J., & Flaitz, C. M. (2000). Oral mucosal melanoma: epidemiology and pathobiology. *Oral Oncol, 36*, 152-169. doi:10.1016/s1368-8375(99)00085-8

Hsieh, R., Nico, M. M., Camillo, C. M., Oliveira, K. K., Sangueza, M., & Lourenco, S. V. (2017). Mutational Status of NRAS and BRAF Genes and Protein Expression Analysis in a Series of Primary Oral Mucosal Melanoma. *Am J Dermatopathol, 39*, 104-110. doi:10.1097/DAD.0000000000000605

Lopez-Graniel, C. M., Ochoa-Carrillo, F. J., & Meneses-Garcia, A. (1999). Malignant melanoma of the oral cavity: diagnosis and treatment experience in a Mexican population. *Oral Oncol, 35*, 425-430. doi:10.1016/s1368-8375(99)00017-2

López, F., Rodrigo, J. P., Cardesa, A., Triantafyllou, A., Devaney, K. O., Mendenhall, W. M., . . . Bradford, C. R. (2016). Update on primary head and neck mucosal melanoma. *Head Neck, 38*, 147-155.

Martín, L. P., Martín-Moro, J. G., Ma, C.-Y., Yu, Z.-W., & Zhang, C.-P. (2014). Melanoma de mucosa intraoral:¿ enfermedad local o sistémica? *Rev Esp Cirug Oral y Maxilofac, 36*, 15-20.

Maymone, M. B. C., Greer, R. O., Kesecker, J., Sahitya, P. C., Burdine, L. K., Cheng, A. D., . . . Vashi, N. A. (2019). Premalignant and malignant oral mucosal lesions: Clinical and pathological findings. *J Am Acad Dermatol, 81*, 59-71. doi:10.1016/j.jaad.2018.09.060

Mikkelsen, L. H., Larsen, A. C., von Buchwald, C., Drzewiecki, K. T., Prause, J. U., & Heegaard, S. (2016). Mucosal malignant melanoma - a clinical, oncological, pathological and genetic survey. *APMIS, 124*, 475-486. doi:10.1111/apm.12529

Nenclares, P., Ap Dafydd, D., Bagwan, I., Begg, D., Kerawala, C., King, E., . . . Harrington, K. J. (2020). Head and neck mucosal melanoma: The United Kingdom national guidelines. *Eur J Cancer, 138*, 11-18. doi:10.1016/j.ejca.2020.07.017

Prasad, M. L., Patel, S. G., Huvos, A. G., Shah, J. P., & Busam, K. J. (2004). Primary mucosal melanoma of the head and neck: a proposal for microstaging localized, Stage I (lymph node-negative) tumors. *Cancer, 100*, 1657-1664. doi:10.1002/cncr.20201

Rambhia, P. H., Stojanov, I. J., & Arbesman, J. (2019). Predominance of oral mucosal melanoma in areas of high mechanical stress. *J Am Acad Dermatol, 80*, 1133-1135. doi:10.1016/j.jaad.2018.07.064

Shen, Z. Y., Liu, W., Bao, Z. X., Zhou, Z. T., & Wang, L. Z. (2011). Oral melanotic macule and primary oral malignant melanoma: epidemiology, location involved, and clinical implications. *Oral Surg Oral Med Oral Pathol Oral Radiol Endod, 112*, e21-25. doi:10.1016/j.tripleo.2011.02.040

Singh, D., Pandey, P., Singh, M. K., & Kudva, S. (2019). Prevalence of malignant melanoma in anatomical sites of the oral cavity: A meta-analysis. *J Oral Maxillofac Pathol, 23*, 129-135. doi:10.4103/jomfp.JOMFP_236_18

Smith, M. H., Bhattacharyya, I., Cohen, D. M., Islam, N. M., Fitzpatrick, S. G., Montague, L. J., . . . Fowler, C. B. (2016). Melanoma of the Oral Cavity: an Analysis of 46 New Cases with Emphasis on Clinical and Histopathologic Characteristics. *Head Neck Pathol, 10*, 298-305. doi:10.1007/s12105-016-0693-x

Sortino-Rachou, A. M., Cancela Mde, C., Voti, L., & Curado, M. P. (2009). Primary oral melanoma: population-based incidence. *Oral Oncol, 45*, 254-258. doi:10.1016/j.oraloncology.2008.04.015

Thompson, J. A. (2002). The revised American Joint Committee on Cancer staging system for melanoma. *Semin Oncol, 29*, 361-369. doi:10.1053/sonc.2002.34115

Topic, B., Masic, T., Radovic, S., Lincender, I., & Muhic, E. (2017). Primary Oral Mucosal Melanomas - Two Case Reports and Comprehensive Literature Review. *Acta Clin Croat, 56*, 323-330. doi:10.20471/acc.2017.56.02.17

Prasad, M. L., Patel, S. G., Huvos, A. G., Shah, J. P., & Busam, K. J. (2004). Primary mucosal melanoma of the head and neck: a proposal for microstaging localized, Stage I (lymph node-negative) tumors. *Cancer, 100*, 1657-1664. doi:10.1002/cncr.20201