

Oral Mucosal Melanoma: A Case Report and Literature Review

Melanoma de la Mucosa Oral: Un Reporte de Caso y Revisión de la Literatura

Daniela Chamba-León¹; Pablo Ruiz-Maila¹; Marx Italo Bravo Muñoz^{2,3}; Hugo Guamán Roldán^{1,4}; Martín Díaz Vintimilla¹; Viviana Gualpa Gómez¹ & Diego Mauricio Bravo-Calderón^{1,4}

CHAMBA-LEÓN, D.; RUIZ-MAILA, P.; BRAVO, M. M. I.; GUAMÁN, R. H.; DÍAZ, V. M.; GUALLPA, G. V. & BRAVO-CALDERÓN, D. M. Oral mucosal melanoma: A case report and literature review. *Int. J. Odontostomat.*, 16(2):331-336, 2022.

ABSTRACT: Oral mucosal melanoma is an unusual and aggressive malignant tumor that mainly affects the palate of men aged between 50 and 60 years. We present a literature review focusing on the etiopathogenesis and the clinicopathologic features of this entity. In addition, we reported a rare case of an oral mucosal melanoma arising in the left cheek of a 60-year-old man. Computed tomography scan revealed infiltration of the tumor to other anatomic structures including the maxillary sinus, the zygomatic bone and the pterygoid processes. Based on its extension, the lesion was considered inoperable and treatment with three-dimensional conformal radiation therapy was proposed but the patient only attended to the first session and died from cancer progression 6 months after the diagnosis. This paper reinforces the importance of inclusion of this malignant tumor in the differential diagnosis of pigmented lesions of the oral mucosa.

KEY WORDS: mucosal melanoma, pigmented lesion, oral mucosa, oral cancer, case report.

INTRODUCCIÓN

Oral mucosal melanoma (OMM) is a rare and highly aggressive malignant neoplasm that accounts for 0.5 % of oral malignant tumors (Sortino-Rachou *et al.*, 2009; Shen *et al.*, 2011; Smith *et al.*, 2016; Singh *et al.*, 2019; Chandan *et al.*, 2020). The tumor is initially asymptomatic and clinically it is observed as a flat pigmented lesion of irregular contour or as an accelerated growth mass of light or dark brown, black, white or even the same color as the adjacent mucosa, therefore, in most cases it is overlooked during the clinical dental examination, which hinders its early diagnosis and worsens its prognosis (Lopez-Graniel *et al.*, 1999; Singh *et al.*, 2019). The aim of this paper is to present a case of melanoma located in an unusual region of the oral mucosa and to review the clinicopathologic features of the lesion.

CASE REPORT

A 60-year-old male presented a burning sensation on the left buccal mucosa with an approximate evolution time of two months. His medical and family history were unremarkable. The intraoral clinical examination revealed a black enlargement of about 0.8cm in its largest diameter and that was interposed with the occlusion of the molars that were restored with amalgam, therefore, amalgam tattoo was formulated as the initial presumptive diagnosis. During surgical resection it was observed that the lesion extended deeply into the tissues and showed intense black color with positivity to the friction test with gauze (Fig. 1).

An incisional biopsy was obtained by removing as much tissue as possible and oral mucosal melanoma

¹ Faculty of Dentistry, University of Cuenca, Cuenca, Ecuador.

² Department of Oncological Surgery, SOLCA Cancer Institute, Cuenca, Ecuador.

³ Faculty of Medicine, University of Cuenca, Cuenca, Ecuador.

⁴ Private Dental Clinic, Cuenca, Ecuador.

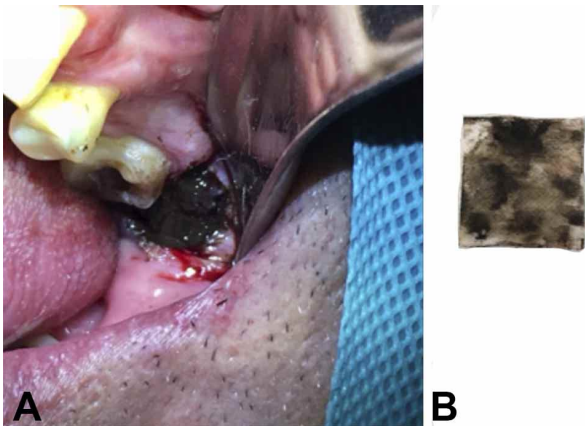


Fig. 1. Intraoperative photographs. A: Left oral mucosa with intense black pigmentation. B: Positive gauze rub test.

was included in the clinical differential diagnosis. Histopathologic examination (Fig. 2) revealed, along the subepithelial connective tissue, several neoplastic melanocytes exhibiting epithelioid, plasmacytoid or spindle-shaped morphology, with hyperchromatic nuclei, some binuclear and with vesicular chromatin. Additionally, infiltration of the skeletal striated muscle and abundant melanin located in the cytoplasm of the neoplastic cells or randomly arranged in the stroma, were observed. Based on the clinical and microscopic features, the definitive diagnosis established was oral mucosal melanoma and the patient was referred to a specialized cancer treatment center, where the diagnosis was confirmed and complementary tomographic studies were obtained.

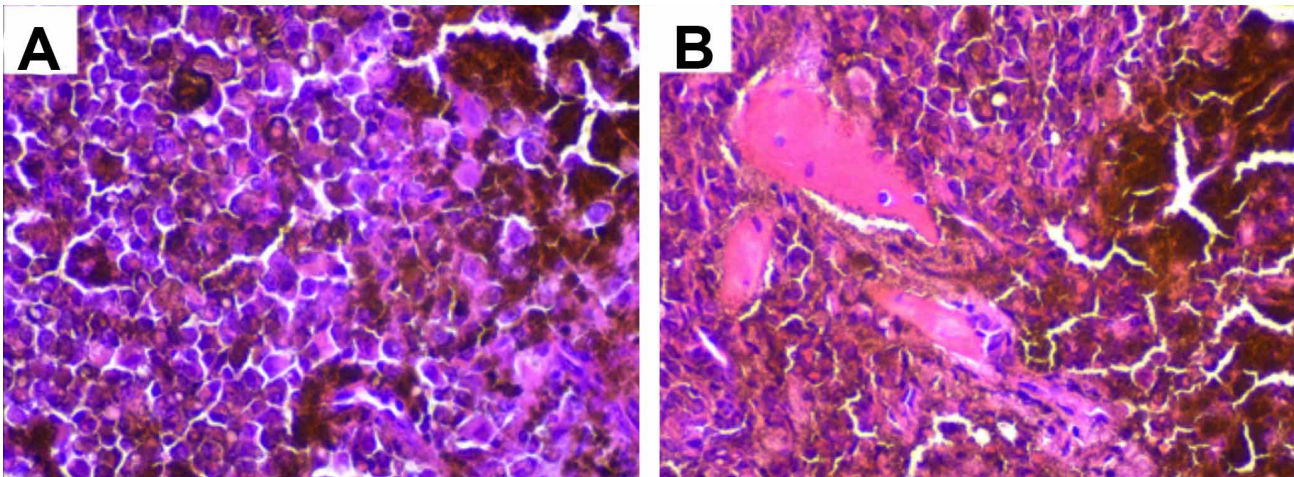


Fig. 2. Histopathologic findings. A: Polymorphic neoplastic cells with clear or pigmented cytoplasm, round or oval hyperchromatic nuclei, and prominent "cherry red" nucleoli. B: Tumor cells with nuclear pleomorphism that infiltrate the striated muscle tissue and with abundant presence of melanin dispersed between the cells.

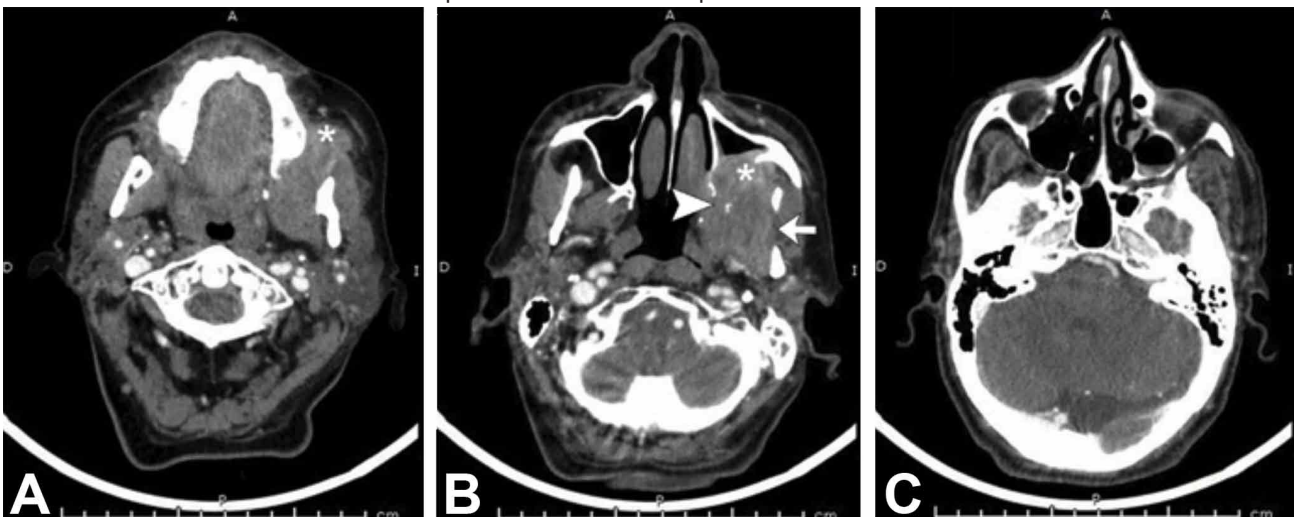


Fig. 3. Cranial Computed Axial Tomography A: Mass delimited in the left zygomatic space in proximity to the mandibular ramus and causing facial volume increase*. B: Tumor extension towards the maxillary sinus and parapharyngeal space with destruction of the posterior wall of the maxillary sinus (asterisk), the pterygoid processes (arrowhead) and the mandibular ramus (arrow). C: Destruction of the left zygomatic arch.

In the computed tomography (CT) cross sections, a soft tissue mass of 50mm x 29mm of diameter was observed, which infiltrated the ipsilateral maxillary sinus, the zygomatic bone and the pterygoid processes (Fig. 3). No locoregional or distant metastasis were verified. Due to its extension, the lesion was considered inoperable and it was proposed a treatment based on three-dimensional conformal radiotherapy with a dose of 40Gy in 8 fractions; however, the patient attended only the first session and died 6 months after the diagnosis.

DISCUSSION

Mucosal melanomas (MM), including those of the head and neck as the OMM, are a type of cancer characterized by the proliferation of atypical melanocytes and the production of high amounts of melanin (Shen *et al.*, 2011; Francisco *et al.*, 2016). Specifically, OMM is more aggressive than their cutaneous counterparts, represents 0.2–8 % of all melanomas, being that, a multicenter study verified that only 8 % of it develops in Hispanic patients, which implies that the rarity of the lesion in this geographic region can lead to it being underestimated, and it may even go unnoticed in its early stages during routine clinical examination (Sortino-Rachou *et al.*, 2009; Smith *et al.*, 2016; Nenclares *et al.*, 2020).

OMM is more prevalent in men with a male to female ratio of 1:0.78, is regularly found between the fifth and sixth decade of life and is most commonly located in the palate (34 %), in the gingiva (8.8 %), with only 4.38 % of these lesions occurring in the buccal mucosa (Sortino-Rachou *et al.*, 2009; Mikkelsen *et al.*, 2016; Smith *et al.*, 2016; Singh *et al.*, 2019).

Clinically, the lesion is usually asymptomatic; moreover, symptomatology can be observed when prosthesis or tooth brushing produce ulceration or bleeding of the entity (Maymone *et al.*, 2019; Singh *et al.*, 2019). In addition, this neoplasm has various clinical manifestations, it can be flat or a mass of accelerated growth, and can exhibit the same color as the underlying mucosa (30 % of the lesions) or more intense colors, such as brown, black, red or purple (Lopez-Graniel *et al.*, 1999; Sortino-Rachou *et al.*, 2009; Smith *et al.*, 2016; Deyhimi *et al.*, 2017; Maymone *et al.*, 2019; Singh *et al.*, 2019; Chandan *et al.*, 2020). Thereby, the clinical differential diagnosis of OMM includes benign pigmented lesions (nevus, melanosis

associated with smoking or drugs, amalgam tattoo, melanoacanthoma, melanotic macule, and vascular lesions), benign inflammatory lesions (epulis, peripheral giant cell granuloma and peripheral ossifying fibroma); and malignant pigmented lesions (Kaposi Sarcoma) (Smith *et al.*, 2016; Deyhimi *et al.*, 2017). Here we reported a case of OMM arising from the buccal mucosa with a great extension to the neighboring tissues and, that based on its small size and proximity with amalgam restorations, was initially considered as a black benign pigmentation. Curiously, the scientific literature reveals that 57.7 % of the clinicians list different benign diagnoses as their first impression of OMM (Smith *et al.*, 2016).

The clinical differentiation of OMM from other pigmented entities of the oral mucosa can be assisted by the use of the gauze rub test, which is a simple, non-invasive and highly sensitive method that is considerate positive for OMM when the gauze is stained of black or dark brown after rubbing the surface of the lesion (Delgado Azañero & Mosqueda Taylor, 2003). According to Delgado Azañero & Mosqueda Taylor (2003), the black color acquired by the gauze is a consequence of the presence of malignant melanocytes laden with high amounts of melanin and the test is positive in 84.6 % of the lesions with diagnosis of OMM confirmed by histopathology.

On the other hand, a negative result of the gauze rub test does not rule out the possibility of OMM (vertical growth pattern or melanocytic variant), especially when the lesion shows the parameters of the ABCDE rule for melanoma, criteria which, together, have a significant sensitivity and specificity (89.3 % and 65.3 %, respectively) in the detection of cutaneous melanomas (Hicks & Flaitz, 2000; Topic *et al.*, 2017). In addition to ABCDE criteria, due to the complexity shown by mucosal melanomas, is suggest the addition of 2 parameters, being: F - feeling (burning, pain or itching) and G - growth (increase in size) (Table I) (Topic *et al.*, 2017).

As described in the present report, the burning sensation on the area and the pigmentation of the gauze suggested the presence of an OMM. Independently of the clinical parameters, the definitive diagnosis of OMM is established by histopathological examination (Sortino-Rachou *et al.*, 2009; Shen *et al.*, 2011; Smith *et al.*, 2016; Deyhimi *et al.*, 2017). Microscopic reports recognize that OMM has radial and/or rapid and early vertical growth, invading superficial tissues and infiltrating deeper tissues; therefore histopathologically,

Table I. ABCDEFG of mucosal melanoma (Topic *et al.*, 2017).

A – Asymmetry: One half is different from the other half.
 B – Margin: An irregular, scalloped or ill-defined margin.
 C – Color: Varies from one area to another with shades from brown to black or sometimes white, blue or white.
 D – Diameter: Melanomas are usually larger than 6 mm, but may be smaller.
 E – Evolution: Skin lesion that looks different from the rest or is changing in shape, size or color.
 F – Feeling: Of burning, pain or itching.
 G – Growth: Increase in size.

it can show three patterns: (a) in situ which is limited to the epithelium with proliferation of atypical melanocytes radially in the basal layer; (b) invasive in which the neoplasm has penetrated the underlying connective tissue with nests of atypical melanocytes in the lamina propria by vertical growth; and (c) combined pattern which is typical in more advanced lesions (Deyhimi *et al.*, 2017; Feller *et al.*, 2017).

Specifically, the malignant melanocytes can show different phenotypes (polyhedral, round, epithelioid, spindle-shaped or pleomorphic) and sizes (Barnes, 2000). They exhibit clear cytoplasm, round to oval nuclei, with one or more hyperchromic ("cherry red") or prominent nucleoli, and single cells can be found along the epithelium (in situ, invasive and combined pattern) or grouped in nests mainly below the interface (invasive and combined pattern), with or without the presence of seromucous glands (in situ pattern) and with intracellular melanin (Barnes, 2000; Coutinho-Camillo *et al.*, 2016). Occasionally, due to the histological diversity of the lesion, auxiliary immunohistochemical (IHC) markers are required to identify S100, Mart1/Melan-A, MITF and HMB45 proteins, which are determinants to confirm the diagnosis of OMM (Table II) (Coutinho-Camillo *et al.*, 2016; Smith *et al.*, 2016; Feller *et al.*, 2017; Topic *et al.*, 2017).

Regarding the etiology of the tumor, it is not fully clarified, in view of the fact that melanocytes may be present in the oral mucosa, especially in melanoderm

people; and in these conditions the specific function of these cells in oral soft tissues is unknown (Martín *et al.*, 2014; Chandan *et al.*, 2020). However, some authors correlate the genesis of the tumor with previous mucosal pigmentation, amalgam tattoos, or external factors such as poorly adapted dental prosthesis, smoking or alcohol consumption, although the appearance of OMM without any apparent predisposing lesion has also been reported; as a result, its identification is complicated, contributing to the delay in treatment and concomitantly to a low survival rate, which fluctuates between 10-25 % in a period of 5 years (Shen *et al.*, 2011; Francisco *et al.*, 2016; López *et al.*, 2016; Mikkelsen *et al.*, 2016; Rambhia *et al.*, 2019; Singh *et al.*, 2019).

In cutaneous melanoma, several mutations have been identified in BRAF, KIT, NRAS genes and in the COX-2 enzyme, most of them induced by UV radiation; however, the low frequency of OMM in association with its late diagnosis do not allow obtaining statistically significant results of mutations in mucosa that help to elucidate the etiology nor to conduct the early diagnosis and prevention of the disease (de Souza do Nascimento *et al.*, 2016; Feller *et al.*, 2017; Hsieh *et al.*, 2017; Mikkelsen *et al.*, 2016; Wong *et al.*, 2019).

Staging is fundamental in order to plan the treatment and to determine the prognosis of the patients, thereby, the American Joint Committee on Cancer (AJCC) uses a staging system for cutaneous

Table II. Immunohistochemical profile of mucosal melanoma.

Protein/marker	Pattern of expression	Percentage of cases in which it is expressed	References
S100	Positive (less specific protein).	90-100 %	Smith <i>et al.</i> (2016)
HMB45	Positive.	95 %	Smith <i>et al.</i> (2016)
C-kit	Positive (high expression rates).	14 %	Coutinho-Camillo <i>et al.</i> (2016)
BRAF	Positive.	5 %	Coutinho-Camillo <i>et al.</i> (2016)
NRAS	Positive.	14 %	Coutinho-Camillo <i>et al.</i> (2016)
p53	Positive (accumulation).	58 %	Coutinho-Camillo <i>et al.</i> (2016)
Cox-2	Positive.	92 %	de Souza do Nascimento <i>et al.</i> (2016)

melanomas, which cannot be applied to their mucosal counterparts, because they, generally at the time of diagnosis, are in stage I which implies that the tumor has invaded nearby tissues in a small area without metastasis in lymph nodes or at a distance (primary localization of the disease) (Thompson, 2002).

For this reason Prasad *et al.* (2004) stipulate that in primary mucosal melanomas without lymph node spread, it is necessary to take into consideration the histological pattern of invasion that was found to be a significant and independent predictor of survival of the patients (Table III) (Thompson, 2002; Prasad *et al.*, 2004).

The main treatment for OMM is radical resection of the lesion with safety margins of up to 2cm, and may include adjuvant treatments to improve the survival rate by up to 10 %, such as: chemotherapy,

radiotherapy, and immunotherapy (interleukin-2 and interferon- alpha) (Martín *et al.*, 2014; Feller *et al.*, 2017; Maymone *et al.*, 2019; Ashok *et al.*, 2020). However, regardless of the therapy administered, the prognosis of OMM is poor with a very high propensity to relapse and a few long-term survivors (Francisco *et al.*, 2016; López *et al.*, 2016).

CONCLUSION

In conclusion, OMM is a rare and aggressive malignant neoplasm that should be considered by the professional when observing pigmented mucosal lesions during routine clinical examination, being useful, for the clinical differential diagnosis, the application of the ABCDEFG criteria in combination with the gauze rub test.

Table III. Staging for mucosal melanoma.

Stage I	Primary disease location.
Level I	Mucosal melanoma <i>in situ</i> .
Level II	Invasion restricted to the lamina propria.
Level III	Melanoma with deep invasion of surrounding tissue, such as bone (in the oral mucosa), cartilage (in the larynx) or skeletal muscle.
Stage II	Primary disease with metastasis to cervical lymph nodes.
Stage III	Distant metastases.

CHAMBA-LEÓN, D.; RUIZ-MAILA, P.; BRAVO, M. M. I.; GUAMÁN, R. H.; DÍAZ, V. M.; GUALLPA, G. V. & BRAVO-CALDERÓN, D. M. Melanoma de la mucosa oral: Un reporte de caso y revisión de la literatura. *Int. J. Odontostomat.*, 16(2):331-336, 2022.

RESUMEN: El melanoma de la mucosa oral es un tumor maligno inusual y agresivo que afecta principalmente al paladar de hombres de entre 50 y 60 años. Presentamos una revisión bibliográfica centrada en la etiopatogenia y las características clínico-patológicas de esta entidad. Además, reportamos un caso raro de melanoma de la mucosa oral que surgió en la mejilla izquierda de un hombre de 60 años. La tomografía computarizada reveló la infiltración del tumor a otras estructuras anatómicas, incluido el seno maxilar, el hueso cigomático y los procesos pterigoideos. En base a su extensión, la lesión se consideró inoperable y se propuso tratamiento con radioterapia conformada tridimensional pero el paciente solo asistió a la primera sesión y falleció por progresión del cáncer 6 meses después del diagnóstico. Este trabajo refuerza la importancia de la inclusión de este tumor maligno en el diagnóstico diferencial de las lesiones pigmentadas de la mucosa oral.

PALABRAS CLAVE: melanoma mucoso, lesión pigmentada, mucosa oral, cáncer oral, reporte de caso.

REFERENCES

- Ashok, S.; Damera, S.; Ganesh, S. & Karri, R. Oral malignant melanoma. *J. Oral Maxillofac. Pathol.*, 24:S82-S85, 2020.
- Barnes, L. *Surgical Pathology of the Head and Neck*. Vol. 1. New York, Informa Healthcare USA Inc., 2000.
- Chandan, S. N.; Shetty, S. K. & Deepa, B. V. Primary malignant melanoma of oral mucosa - Report of two cases. *Contemp. Clin. Dent.*, 11(2):195-8, 2020.
- Coutinho-Camillo, C. M.; Lourenço, S. V. & Soares, F. A. Head and neck: Primary oral mucosal melanoma. *Atlas Genet. Cytogenet. Oncol. Haematol.*, 20:52-60, 2016.
- de Souza do Nascimento, J.; Carlos, R.; Delgado-Azanero, W.; Mosqueda Taylor, A.; de Almeida, O. P.; Romanach, M. J. & de Andrade, B. A. Immunohistochemical expression of cyclooxygenase-2 (COX-2) in oral nevi and melanoma. *J. Oral Pathol. Med.*, 45(6):440-3, 2016.
- Delgado Azañero, W. A. & Mosqueda Taylor, A. A practical method for clinical diagnosis of oral mucosal melanomas. *Med. Oral*, 8(5):348-52, 2003.
- Deyhimi, P.; Razavi, S. M.; Shahnasari, S.; Khalesi, S.; Homayoni, S. & Tavakoli, P. Rare and extensive malignant melanoma of the oral cavity: report of two cases. *J. Dent. (Shiraz)*, 18(3):227-33, 2017.
- Feller, L.; Khammissa, R. A. G. & Lemmer, J. A review of the aetiopathogenesis and clinical and histopathological features of oral mucosal melanoma. *ScientificWorldJournal*, 2017:9189812, 2017.

- Francisco, A. L. N.; Furlan, M. V.; Peresi, P. M.; Nishimoto, I. N.; Lourenço, S. V.; Pinto, C. A.; Kowalski, L. P. & Ikeda, M. K. Head and neck mucosal melanoma: clinicopathological analysis of 51 cases treated in a single cancer centre and review of the literature. *Int. J. Oral Maxillofac. Surg.*, 45(2):135-40, 2016.
- Hicks, M. J. & Flaitz, C. M. Oral mucosal melanoma: epidemiology and pathobiology. *Oral Oncol.*, 36(2):152-69, 2000.
- Hsieh, R.; Nico, M. M. S.; Camillo, C. M. C.; Oliveira, K. K.; Sanguenza, M. & Lourenço, S. V. Mutational status of NRAS and BRAF genes and protein expression analysis in a series of primary oral mucosal melanoma. *Am. J. Dermatopathol.*, 39(2):104-10, 2017.
- López-Graniel, C. M.; Ochoa-Carrillo, F. J. & Meneses-García, A. Malignant melanoma of the oral cavity: diagnosis and treatment experience in a Mexican population. *Oral Oncol.*, 35(4):425-30, 1999.
- López, F.; Rodrigo, J. P.; Cardesa, A.; Triantafyllou, A.; Devaney, K. O.; Mendenhall, W. M.; Haigentz Jr, M.; Strojjan, P.; Pellitteri, P. K.; Bradford, C. R.; *et al.* Update on primary head and neck mucosal melanoma. *Head Neck*, 38(1):147-55, 2016.
- Martín, L. P.; Martín-Moro, J. G.; Ma, C. Y.; Yu, Z. W. & Zhang, C. P. Melanoma de mucosa intraoral: ¿enfermedad local o sistémica?. *Rev. Esp. Cir. Oral Maxilofac.*, 36(1):15-20, 2014.
- Maymone, M. B. C.; Greer, R. O.; Kesecker, J.; Sahitya, P. C.; Burdine, L. K.; Cheng, A. D.; Maymone, A. V. & Vashi, N. A. Premalignant and malignant oral mucosal lesions: Clinical and pathological findings. *J. Am. Acad. Dermatol.*, 81(1):59-71, 2019.
- Mikkelsen, L. H.; Larsen, A. C.; von Buchwald, C.; Drzewiecki, K. T.; Prause, J. U. & Heegaard, S. Mucosal malignant melanoma - a clinical, oncological, pathological and genetic survey. *APMIS*, 124(6):475-86, 2016.
- Nenclares, P.; Ap Dafydd, D.; Bagwan, I.; Begg, D.; Kerawala, C.; King, E.; Lingley, K.; Palleri, V.; Paterson, G.; Payne, M.; *et al.* Head and neck mucosal melanoma: The United Kingdom national guidelines. *Eur. J. Cancer*, 138:11-8, 2020.
- Prasad, M. L.; Patel, S. G.; Huvos, A. G.; Shah, J. P. & Busam, K. J. Primary mucosal melanoma of the head and neck: a proposal for microstaging localized, Stage I (lymph node-negative) tumors. *Cancer*, 100(8):1657-64, 2004.
- Rambhia, P. H.; Stojanov, I. J. & Arbesman, J. Predominance of oral mucosal melanoma in areas of high mechanical stress. *J. Am. Acad. Dermatol.*, 80(4):1133-5, 2019.
- Shen, Z. Y.; Liu, W.; Bao, Z. X.; Zhou, Z. T. & Wang, L. Z. Oral melanotic macule and primary oral malignant melanoma: epidemiology, location involved, and clinical implications. *Oral Surg. Oral Med. Oral Pathol. Oral Radiol. Endod.*, 112(1):e21-5, 2011.
- Singh, D.; Pandey, P.; Singh, M. K. & Kudva, S. Prevalence of malignant melanoma in anatomical sites of the oral cavity: A meta-analysis. *J. Oral Maxillofac. Pathol.*, 23(1):129-35, 2019.
- Smith, M. H.; Bhattacharyya, I.; Cohen, D. M.; Islam, N. M.; Fitzpatrick, S. G.; Montague, L. J.; Damm, D. D. & Fowler, C. B. Melanoma of the oral cavity: an analysis of 46 new cases with emphasis on clinical and histopathologic characteristics. *Head Neck Pathol.*, 10(3):298-305, 2016.
- Sortino-Rachou, A. M.; Cancela, M. C.; Voti, L. & Curado, M. P. Primary oral melanoma: population-based incidence. *Oral Oncol.*, 45(3):254-8, 2009.
- Thompson, J. A. The revised American Joint Committee on Cancer staging system for melanoma. *Semin. Oncol.*, 29(4):361-9, 2002.
- Topic, B.; Masic, T.; Radovic, S.; Lincender, I. & Muhic, E. Primary oral mucosal melanomas - Two case reports and comprehensive literature review. *Acta Clin. Croat.*, 56(2):323-30, 2017.
- Wong, K.; van der Weyden, L.; Schott, C. R.; Foote, A.; Constantino-Casas, F.; Smith, S.; Dobson, J. M.; Murchison, E. P.; Wu, H.; Yeh, I.; *et al.* Cross-species genomic landscape comparison of human mucosal melanoma with canine oral and equine melanoma. *Nat. Commun.*, 10(1):353, 2019.

Corresponding author:
Diego Mauricio Bravo-Calderón
El Paraiso and 10 de Agosto
Avenues 010102, Cuenca
Azuay
ECUADOR

E-mail: diegom.bravoc@ucuenca.edu.ec