



(CASE STUDY)



## Psychoneuroimmunoendocrine syndrome with impact on the stomatognathic system

María Lourdes Rodríguez <sup>1,2,\*</sup> and Zulema Juana Casariego <sup>3</sup>

<sup>1</sup> University of Cuenca, Dentistry school, Professor in the Department of Semiology and Diagnostic Clinic. Cuenca-Ecuador

<sup>2</sup> University of Buenos Aires, Dentistry school, Student of PhD in Oral Microbiology and Immunology. Buenos Aires-Argentina.

<sup>3</sup> Full member of the Honorable Argentine National Academy of Dentistry. Buenos Aires-Argentina.

Publication history: Received on 01 September 2020; revised on 16 September 2020; accepted on 20 September 2020

Article DOI: <https://doi.org/10.30574/wjarr.2020.7.3.0334>

### Abstract

Psychoneuroimmunoendocrinology studies the interaction between the psyche, neural, endocrine and immune function. There are not many works in the literature on the effect of chronic stress on the stomatognathic system. The objective of this article is to present a clinical case with a group of stomatological manifestations. There are, alterations in systemic stress mediators such as cortisol, and local and systemic immunological disorders. Those could be depend on clinical, biochemical and pathological characteristics established in the skin, as antecedents. We propose that the set of its manifestations are the result of an imbalanced psychoneuroimmunoendocrine axis with overactivation of the HPA axis. It could be also favored, by the cyclothymic personality and anxious profile of the patient, determined after a professional psychological study. This work will allow us to consider the "Psychoneuroimmunology" in the etiopathogenesis of disorders such as temporomandibular joint dysfunction, geographic tongue, and cheilitis.

**Keywords:** Psychoneuroimmunology; Stomatognathic system; Benign migratory glossitis; Cheilitis; Temporomandibular joint; Case report.

### 1. Introduction

Psychoneuroimmunoendocrinology is the science that study the interaction between the psyche, neural and endocrine functions, and the immune response. These systems can interact each others through two ways: Changes in endocrine and neural functions could alter the immune response, stimulating the immune response and modifying the functionality of the endocrine and the central nervous systems (CNS) [1, 2]. The origin of Psychoneuroimmunology as a scientific discipline dates back to 1970, when Ader and Cohen published their work entitled "Behavior conditioning of immunosuppression". They had propose a functional link between the immune system and the nervous system. This theory proposed that the immune response generates cytokines that stimulate the CNS [3]. This brain stimulation could activate the hypothalamic-pituitary-adrenal (HPA) axis, and at the same time, probably could suppress the immune response through the secretion of glucocorticoids and corticotropin-releasing hormone, depending on whether this release can be persistent [4].

Few studies explain the relationship between skin diseases and disorders of the stomatognathic system (oral cavity and associated organs), in relationship with an altered psychoneuroimmunoendocrine axis [4,5,6,7,8]. We must consider that these three systems are connected from the embryological and functional point of view. Indeed, all three come from the ectoderm; but the connection between the buccal mucosa, as a component of the stomatognathic system, and the nervous system is more intimate. That's why the lamina propria or chorion, that supplies and supports the epithelium

\* Corresponding author: María Lourdes Rodríguez  
Ecuador, Cuenca, Sector Río Amarillo (CP: 010219), Calle del Romero y El Tejar.

that lines the buccal mucosa, recognizes an ectomesenchymal origin (from the cranial neural crest) [9]. The functional relationship that has been proposed between the skin and the stomatognathic system, with the nervous system, is explained on the effect of neuropeptides on the intrinsic and extrinsic cell populations that make up the skin and oral mucosa, which express receptors for such molecules. These interactions between neuropeptides and their receptors (expressed by keratinocytes) have been proposed to be essential for the regulation of localized immune responses in the skin and mucosa [10]. Parallel to this, studies suggest that, anxiety disorders, are linked to the hyperactivity of the limbic system, that increase the neuropeptide substance P. It happens at the level of the skin and / or mucous membranes. All this factors generate a local inflammatory response, based on IL-1 production by resident keratinocytes, fibroblasts, and macrophages, endothelial activation with increased expression of adhesion molecules, and the consequent extravasation of lymphocytes, monocytes, and eosinophils. The effect on mast cells results in degranulation and release of histamine and leukotrienes. Furthermore, the effect of substance P on lymphocytes has been reported to increase immunoglobulin synthesis by up to 300%. Over monocytes, it increases the release of inflammatory cytokines such as IL-1, IL-6, TNF, and INF- $\gamma$  [11, 12]. All this immune response to the stimulation of the neuropeptide substance P, affects increasingly the situations of stress and anxiety. It was published as the pathophysiological basis of psycho-immuno-mediated skin diseases, such as rosacea, lichen planus, seborrheic dermatitis [5]. The diseases of oral mucosa, such as: geographic tongue, or benign migratory glossitis [13], recurrent aphthous stomatitis (RAS) [8], periodontal disease [14], and burning mouth syndrome (SBA) [6] also were recognized of a psycho-immunological origin.

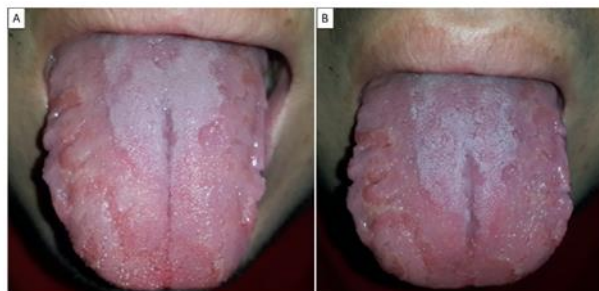The main objective of the present work is to report a clinical case in which anxiety disorder, endocrine alterations, temporomandibular joint (TMJ) dysfunction, factitious lesions, and geographic tongue are recognized as a framework of a picnic biotype. As a secondary objective, we propose a review of the literature to search a biological explanation to each of the manifestations detected in the patient's stomatognathic system.

This work will help dental professionals and stomatologists to consider psychoneuroimmunology in the pathogenesis of frequently consulted stomatognathic disorders such as TMJ dysfunction, geographic tongue and cheilitis. We highlight the importance of a multidisciplinary approach in the management of cases such as the one presented in this report.

## 2. Case report

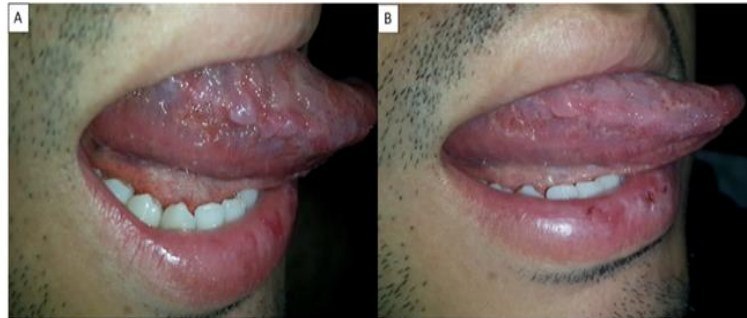A 24-year-old male patient, single, with a mixed racial component, comes to stomatological consultation, due to an peculiar noise and transitory pain in his TMJ during chewing episodes, for a considerable time. The patient reports hypertension and gastric cancer as a family medical history. On a medical level, the patient reports a history of orthopedic surgeries, urethritis, hospitalization for pneumonia; and hypercaloric diet. Orally, the patient reports third molar surgeries, root canals and restorations without some complications. Additionally, the patient reveals constant nibbling of the lower lip, and shedding of scales.

On general physical examination, the patient seems to be conscious, reflecting a picnic-brevilinear biotype. His vital signs were normal. The extra-oral examination revealed a brachifacial morphotype, auscultating noises during the execution of laterally mandibular movements. Lymph node examination revealed asymmetric submaxillary adenopathy; presence of dryness, scaling and blood crusts mainly affecting the central third of the lower labial semi-mucosa. The intraoral examination showed alterations of the tongue. It revealed scrotal appearance, exhibiting irregular atrophic-erythematous lesions with a meandering appearance. Those involved the anterior two thirds of the dorsal surface, both hemispheres, lateral borders, and ventral right side, and some times, surrounded by a keratotic halo, deficit of filiform papillae, totally asymptomatic. At the follow-up of the patient, migratory behavior of these lesions was verified (Figs. 1-3).



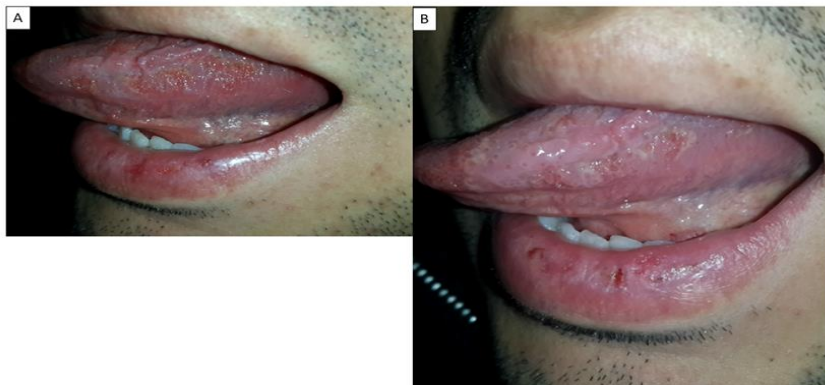
**Figure 1** Clinical appearance of tongue lesions

Note: **A.** Tongue, dorsal surface, involving both hemispheres in the anterior two thirds, exhibits atrophic erythematous areas with a serpentine appearance, delimited in some areas by a faint keratotic halo. Note the deficit of filiform papillae. **B.** The change in the global aspect of the tongue with respect to A. Note the appearance of a new atrophic area in the midline of the anterior third of the tongue, on the dorsal aspect, in a delayed session.



**Figure 2** Clinical appearance of tongue lesions.

Note: **A.** Tongue, right border, involving part of the dorsum, and ventral aspect shows serpentine erythematous atrophic lesions, delimited in some cases by a faint yellowish-white halo. **B.** Note the change in the appearance and location of the lesions in delayed session.



**Figure 3** Clinical appearance of tongue lesions.

Note: **A.** Tongue, left border, involving part of the dorsal aspect, exhibits atrophic-erythematous lesions with a serpentine appearance, delimited by a faint yellowish-white halo. **B.** In a delayed session, note the change in the appearance and distribution of the atrophic lesions, which now take on a more annular appearance.

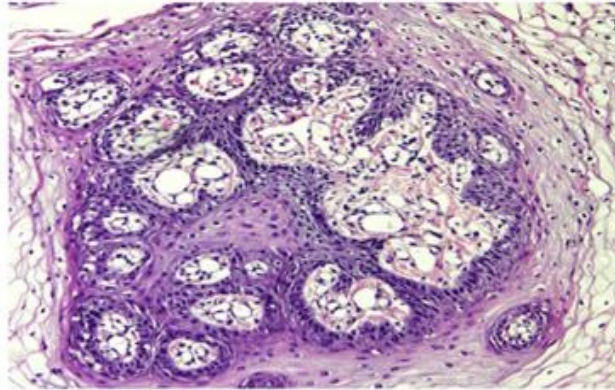
The palpation of the external and internal pterygoid muscles was more sensitive. There were no identifications of dental facets over chewing surfaces, or abfractions on tooth necks.

Given the expressed clinical picture, was proposed as a diagnostic hypothesis a case of psychoneuroimmunoendocrine syndrome with an impact on the stomatognathic systems.

To confirm our hypothesis, the following complementary tests were requested: Complete blood count, blood glucose, lipid profile, vitamin B12 dosage, blood cortisol dosage, serum IgE level; and anxiety test performed by a certified psychologist. Magnetic resonance of the TMJ was indicated to assess the location of the interarticular disc and other attached soft tissues, which only this method allows us to record with sufficient sensitivity and specificity [15].

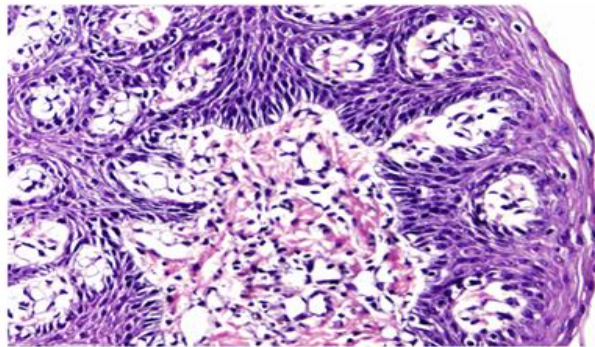
The tongue lesions were biopsied for histopathological examination. Figures 4-6 demonstrate a parakeratotic stratified flat epithelium, acanthotic in certain areas and thinned in others with significant flaking. Additionally, the specimen shows intercellular edema, and leukocyte infiltrate invading the epithelium, reaching the superficial layers. The

underlying chorion demonstrates abundant vascular beds, with endothelial cell hypertrophy, mononuclear cell extravasation, and areas of the epithelium infiltrated by mononuclear leukocytes. All this figures showed a picture of inflammation. The section did not reveal filiform or fungiform papillae.



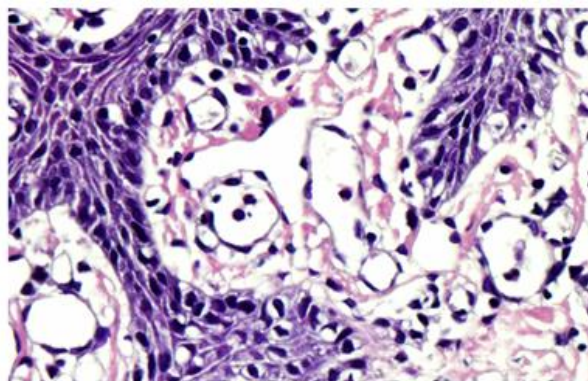
**Figure 4** Histopathological study of tongue biopsy, involving atrophic and hyperkeratotic lesions on the dorsum of the tongue.

**Note:** Panoramic view (10X) of a lingual specimen cut transversely, showing a parakeratinized stratified flat epithelium, thinned in certain areas and acanthotic in others; with significant desquamation and leukocyte infiltration. In the section, neither filiform nor fungiform papillae are observed. The underlying chorion shows abundant blood vessels, with extravasation of mononuclear cells, and areas of leukocytes invading the epithelium.



**Figure 5** Histopathological study of tongue biopsy, involving atrophic and hyperkeratotic lesions on the dorsum of the tongue.

**Note:** Cross section of specimen analyzed with 40X objective. Note the partial acanthosis of the epithelium, with intercellular and intracellular edema. Some degenerated keratinocytes. The abundant vascularization of the chorion is noteworthy; in addition to the close interaction between the basal keratinocytes and the mononuclear infiltrate.



**Figure 6** Histopathological study of tongue biopsy, involving atrophic and hyperkeratotic lesions on the back.

**Note:** Specimen analyzed with 100X magnification. Note the vascular role of the chorion with abundant vascular beds, some are ectatic. The epithelium shows intercellular and intracellular edema, and areas of invasion by mononuclear leukocytes.

The study of TMJ magnetic resonance reported lateral dislocation of the interarticular disc at the state of closure (Data not revealed).

Laboratory studies reported an increase in blood cortisol levels, as well as serum IgE levels (Table 1).

**Table 1** Results of the laboratory studies requested from the patient in the first consultation.

Type of exam	Result
Hemogram	Normal
Blood glucose	Normal
Lipid profile	Hypercholesterolemia to LDL
B12 vitamin	Normal
Cortisol at 8am	50mcg/dL
Total serum IgE level	28UI/mL (Class 4 high positive) [16]

The psychological test generated an anxiety percentile of 0.74; being considered normal up to 0.60. Denoting anxiety disorder with cyclothymic personality (Data not revealed).

The definitive stomatological diagnoses of the patient were the following: 1) *Myalgia type II with internal alteration type I*, according to the Trueleve clinical criteria for TMJ disorders proposed in 1992 [17]. 2) *Factitious cheilitis* and 3) *Typical benign migratory glossitis*.

The indication of treatment involved: a) Cognitive psychotherapy with a competent professional [18]; b) Topical antihistamines [19]; c) Diet poor in allergens, irritants, and carbohydrates (2, 18); d) Control of hot and spicy food or drinks [19]; e) Lipstick with moisturizers and ultraviolet protection [19]; e) Anti-inflammatory / muscle relaxants, f) Interconsultation with an immunologist and oral rehabilitator.

### 3. Discussion

The signs and symptoms of the stomatognathic system of this patient can be interpreted as manifestations of an altered psychoneuroimmunoendocrine axis, based on the following considerations:

The patient has a picnic biotype according to Ernst Kreshtmer (German psychiatrist and neurologist), He had recognized in his work "*Constitution and character*", the relationship between temperament and body constitution. Manic-depressive psychosis is generally suffered by those people with a Picnic body type characterized by the predominance of transverse dimensions, medium height, short and wide neck, head and voluminous abdomen. These characteristics were identified in our patient (coinciding with the anxiety disorder identified through his nibbling habit). Indeed, studies show that, anxiety disorder is a comorbidity of bipolar disorder [20], and according to Kreshtmer, picnics are prone to bipolar cyclothymic temperament. Studies report a 70% prevalence of bipolar disorder in subjects with a brevilinear-picnic biotype [21]. This cyclothymic personality associated with a stressful environment, promotes the chronicity of perceived stress.

The patient presented signs and symptoms of a dysfunction in TMJ. Also, the magnetic resonance study showed disc displacement.

In order to consider all these findings, the question arises to the point of: ¿Joint dysfunction is a manifestation of a psycho-emotional disorder? In the same way, McCreary and collaborators, described in 1991 the so-called «psychophysiological hypothesis». They postulated that certain personality are predisposed to suffer stress symptoms

such as increasing the muscular tension and hyperactivity of the TMJ, with consequence of dysfunction of the masticatory apparatus [22]. According to Simonic-Kocijan et al. (2009) and Durham et al. (2008), psycho-emotional disturbances are important risk factors associated with chronic pain [23, 24]. Patients with mental disorders, anxiety problems, post-traumatic stress, depression, somatization, irritable bowel syndrome, idiopathic pruritus, hysteria and hypochondriasis, as well as psychosocial problems are associated with TMJ pain syndrome and dysfunction as possible causes of temporomandibular disorders [25-27].

In addition, we have observed that the patient had self-inflicted traumatic lesions in the lower lip semi-mucosa, compatible with factitious cheilitis. This clinical entity is semiologically described as dryness, flaking, cracking, or fissuring of the lips due to various habits, including biting or continual licking of the organ [28]. In 1921 Brocq suggested that some inflammatory disorders of the lips could be due to nervous instability [29]. French have described a condition known as *le tic des lèvres*, in which manipulation of the lips produces cheilitis or exacerbates an existing one. The presence of hematic or meliceric crusts can confuse the diagnosis, and direct anamnesis and complementary tests towards an infectious, actinic, drug or allergic etiology. Hence, the diagnosis of factitious cheilitis is constructed by ruling [29]. In this particular case, it was very easy to establish the origin of the inflammatory lesions identified on the patient's lip, by detecting the nibbling habit through questioning. This antecedent, associated with its picnic biotype and the relationship that this morphotype has shown, induced psychiatric disorders, that resulted on anxiety. It was testified by a certified psychologist. Evidently the traumatic lesions observed in the semi-mucosa of the lower lip showed a psychiatric origin. In addition, previous reports of exfoliative cheilitis and glandular cheilitis have failed to clarify the distinction between these conditions and factitious cheilitis. We can mention Tyldesley who described in 1973 a case of exfoliative cheilitis that was resolved after reassurance and removal of stressors [30]. Similarly, one of Brooke's patients with exfoliative cheilitis, noted improvement after optimizing his dental hygiene and removing a stressful environment [31]. In a review of glandular cheilitis Woodburne and Philpott's recognized that, emotional disturbances were important as contributing factors to this clinical entity [32].

Upon the observation of the presented patient with erythematous atrophic lesions of annular appearance, delimited by an infrequent keratotic halo, and that affected the back, edges and part of the right ventral surface of the tongue; showing migratory behavior during controls we can say that this picture is compatible with a benign migratory glossitis, also called geographic tongue, or erythema migrans. In 2009, Reyes Velasquez et al., pointed out that geographic tongue can associate various factors [33], being the psychoimmunological factor the most reported in the literature. For example, Marshall Bavuriza et al., observed in their study that children with different geographic tongue were behaviorally dissimilar (restless, disorderly, and nervous) from the group without the same geographic tongue [13]. Other authors who have found a link between this clinical entity with emotional stress and immunological alterations are, for example: Redman 1972 [34], Costa et al. 2009 [35], Goregen et al. 2010 [36], and Ching et al. 2013 [37]. A recent systematic review published in 2017 on geographic tongue, identified both intra and extraoral comorbidities such as allergies, psoriasis, anxiety, oral candidiasis and dental caries, frequently associated with this clinical entity. Based on these findings, the group suggested to consider geographic tongue as a marker of severity of detected comorbid diseases [38]. Regarding the relationship between geographic tongue and atopy, the case-control study by Rezaei et al., published in 2019, they evaluated the salivary antioxidant status and salivary IgE levels in patients with geographic tongue. The authors reported that IgE levels were significantly increased in the group with geographic tongue, compared to the control group. However, they did not detect significant differences between the study groups regarding salivary antioxidant activity. The group suggested that IgE levels may function as an indicator of geographic tongue hypersensitivity [39]. (Actually, levels of IgE are related with Allergy)

About the possible etiopathogenic factors documented in the literature of geographic tongue, we were able to recognize in our patient: a) Increase in serum IgE levels, and b) Anxiety disorder linked to chronic stress.

In summary, based on the repetitive episodes of pneumonia that led hospitalizations; the anxiety disorder and chronic stress verified by professional test; the increase in cortisol in the blood, the atopic profile manifested in an increase in IgE and possibly in tongue lesions compatible with benign migratory glossitis, the TMJ disorder and cheilophagia causing self-inflicted cheilitis, conditions linked to the psycho-emotional state, we consider: that everything is part of a psychoneuroimmunoendocrine syndrome, triggered by the chronic stress state of the patient. The literature suggests that chronic stress overactivates the HPA axis, causing an increase in the levels of cortisol in the blood, and of other hormones such as corticotropin-releasing hormone (CRH) [40].

Although the chronically released cortisol inhibits the inflammatory response, by having an immunosuppressive effect (other hormones of the HPA axis such as CRH.) This relationship is bidirectional, since the activation of the peripheral inflammatory response can stimulate the HPA axis [41]. We hypothesize that these products of the systemic inflammatory response, generated by the activation of lymphocytes and macrophages, access by local circulation to the

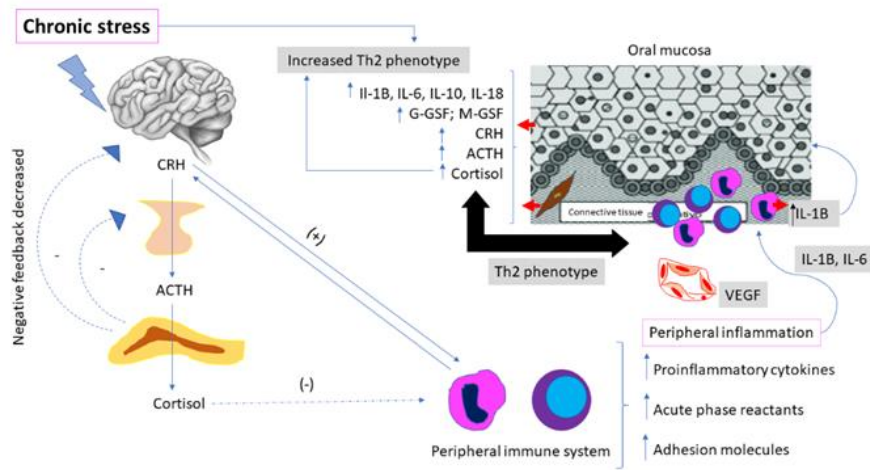
chorion or lamina propria of the specialized mucosa of the tongue. They could activate resident macrophages or histiocytes, which respond with the release of more inflammatory cytokines, attracting to the site T lymphocytes. The release of cytokines such as IL-1B, contribute, mainly by macrophages and dendritic cells, to the activation of lymphocytes and keratinocytes of the epithelium of the specialized mucosa of the tongue, leading to a persistent glosso-inflammatory state [9, 41]. This persistent inflammation in the lingual connective tissue could be responsible of the sectorized degeneration of the epithelium of the tongue, resulting clinically in depapillate or atrophic areas, as the case presented. (Fig. 7). This hypothesis is supported by the work of Soria et al., entitled, “*Psychoneuroimmunology of mental disorders*”. It is proposed that the products of systemic inflammation, promoted and enhanced by chronic stress, can cross the blood-brain barrier and trigger a neuroinflammatory reaction [41].

Histopathology lesions of the tongue revealed abundant vascular beds in the subepithelial chorion. This picture could be explained by the role of IL-1B, released by macrophages and activated keratinocytes, that determines a state of persistent activation of the vascular endothelium, promoting the expression of the receptor for the vascular endothelial growth factor (VEGFR). The ligand for this receptor (VEGF), an angiogenesis-promoting cytokine, is supplied by activated mesenchymal cells such as fibroblasts. Indeed, it is known that the expression of VEGF-A is positively regulated in the epidermis of inflammatory dermatoses such as psoriasis, contact dermatitis, and atopic dermatitis. In these disease models, VEGF-A has been shown to be significantly increased in the epidermis of lesions, and this overproduction results in vessel dilation and hyperpermeability. Prolonged dilation of the cutaneous capillaries has been reported in typical atopic dermatitis lesions, resulting in persistent erythema and edema. VEGF-A is considered a powerful mediator that produces hyperpermeability of blood vessels and endothelial proliferation. It could be involved in the persistent edema and erythema of atopic dermatitis [4, 42, 43]. Additionally, has been reported the ability of chronic stress to mediate the secretion of cytokines such as IL-6 and VEGF [44, 45].

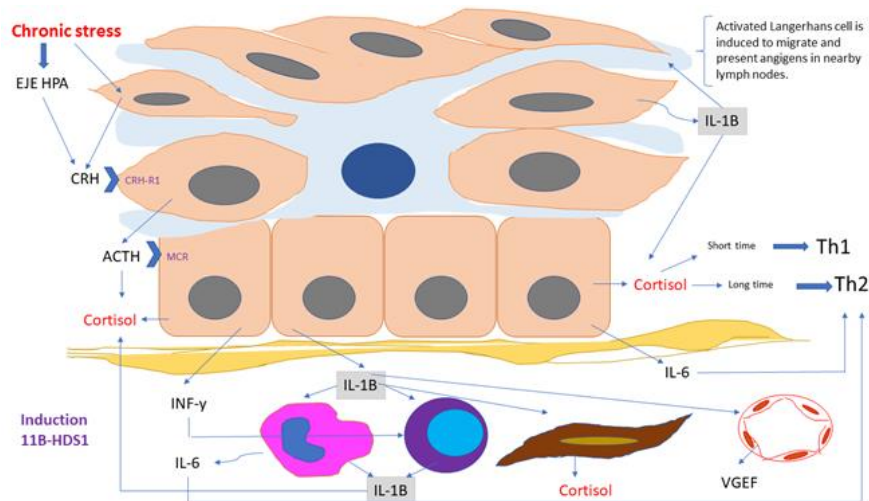
The epithelial and subepithelial changes observed in the tongue specimen are compatible with those described by Marchena et al., in their review article on the etiology of geographic tongue published in 2015, in the European Journal of Odonto-stomatology [46].

The activation of the keratinocytes, under chronic stress, also leads to the release of other key cytokines, such as IL-6, IL-10 and IL-18. These molecules stimulate humoral immunity by promoting the activation of B cells and favoring their differentiation into antibody-producing plasma cells [4]. Given the increased serum level of total IgE in the exposed clinical case, it is likely that the pro-inflammatory state of the patient is polarized to a Th2 immune phenotype, promoting atopic states. Coincidentally, the geographic tongue identified in the patient has been associated with states of atopy [36, 38, 39]. Figure 8 schematically shows the response of the buccal mucosa to psychological stress, in which we can observe the high prominence of the keratinocyte in the modulation of the immunoinflammatory response to a state of acute and chronic stress. Indeed, according to Pondeljok in his review, we presume that the keratinocyte is a cell of the immune system that forms a separate compartment, since it is capable of secreting and responding to cytokines and presenting antigens [4]. In parallel, Slonimski and his group demonstrated the neuroendocrine properties of the skin through its secretions and the ability to respond to hormones, neurotransmitters and neuropeptides [47]. These products are analogous to the hormones, neurotransmitters and neuropeptides of the central HPA system. This means that the keratinocyte exerts neuroendocrine control locally, while the HPA axis does so at the systemic level [48] (Fig. 8).

In the presented case, psychologists detected a personality tending to a bipolar profile. Soria in his 2017 review, on psycho-neuroimmunology of mental disorders, proposes an association between the bipolar profile (as the case presented) and pro-inflammatory states. Additionally, systemic pro-inflammatory states accentuate manic-depressive symptoms, given the response of to the inflammatory stimulus to nervous system. [41].



**Figure 7** Effect of psychological stress on the peripheral immune system and oral mucosa.



**Figure 8** Effect of psychological stress on the oral mucosa.

**Note for Figures 7 and 8:** Chronic stress directly influences the endocrine and central nervous systems, exacerbating the HPA axis. This axis produces CRH, ACTH, and cortisol. Chronic CRH release activates the systemic inflammatory response with a Th1 phenotype. Whereas cortisol inhibits this response when it is chronically released. Activated CD4 T lymphocyte and macrophage release IL-1B. In parallel, the chronically released cortisol promotes the secretion of IL-6 in the macrophage. Both cytokines access the chorion of the buccal mucosa via hematogenous. IL-1B activates the keratinocyte, promoting the secretion of more IL-1B, which acts via autocrine on the epithelium, and paracrinely on the macrophage, T lymphocytes, endothelium, and dendritic cells. The latter migrate to the lymph nodes to promote the activation and clonal expansion of T cells. For its part, the activated endothelium expresses VEGFR, promoting angiogenesis. Chronic stress directly and indirectly influences the keratinocyte and fibroblast, mediating the production of CRH. This hormone induces the keratinocyte and fibroblast to produce ACTH, by CRH-receptor. ACTH promotes local cortisol secretion in both cells, by the melanocortin receptor (MCR). This chronically released cortisol promotes the differentiation of LT-CD4 into LT-Th2. This phenotype is exacerbated by the induction of IL-6, IL-10, and IL-18 contributed by the keratinocyte. It has been shown that the hormone CRH (released locally and centrally) induces the secretion of IL-10 in the keratinocyte. While the hormone ACTH (released locally and centrally) induces the keratinocyte to secrete IL-18.

It was identified adherence to a hypercaloric diet in the patient, reflected in an increase in LDL cholesterol in the blood (the literature establishes in an state of chronic stress, body’s behavior is translated into pernicious habits such as alcohol and calories consumption, and smoking). This behavioral response is variable from one subject to another, and is influenced by personality traits, socioeconomic status, education and gender [2].



Our patient have had at the beginning a good adherence to the established treatment plan. It was reflected in his availability to attend the psychological study, but unfortunately, he did not continue. We consider that the follow-up of these patients should be permanent, due to the cyclothymic personality that characterizes subjects with a manic depressive personality, such as the reported case.

---

#### 4. Conclusion

Based on the pathological, biochemical and clinical findings of our patient, we postulate that the geographic tongue presented in this case is a form of atopic stomatitis associated with chronic stress. Based on this, in the event of lesions compatible with geographic tongue, TMJ symptoms and self-inflicted labial lesions, in individual or mixed presentation, we recommend the evaluation of the hypothalamic-pituitary-adrenal axis through serum cortisol, ACTH, and CPH; and the values of the humoral immune response, which under chronic stress conditions is exacerbated by polarization of the Th2 phenotype, and translated into high levels of IgE in serum and in other fluids such as saliva. Additionally, we recommend dosing serum levels of IL-6, IL-10, and IL-18, cytokines secreted by activated keratinocytes under a state of chronic stress, and which promote the Th2 phenotype, which characterizes states of atopy.

We suggest that the expression of VEGF-A in lesions such as geographic tongue must be studied by immunohistochemistry.

The presented case will allow dentists and stomatologists to consider the effect of stress on the brain and on the rest of the systems. These systemic effects, which are reflected at the endocrine, immune, neurological, emotional and behavioral levels, are the result of the set of responses that the body mounts to the stressor stimulus. But, when stress becomes chronic, chemical changes in the brain are generated that ultimately lead to a body imbalance, where the mouth and / or the stomatognathic system can be a target for such an imbalance.

---

#### Compliance with ethical standards

##### *Acknowledgments*

We express our gratitude to our patient for his collaboration and trust.

##### *Disclosure of conflict of interest*

The authors declare that this article has not received funds from any entity, for its preparation and publication; and we have no conflicts of interest.

##### *Statement of informed consent*

Informed consent was obtained for the publication of this case report.

---

#### References

- [1] Ader R, Cohen N. Psychoneuroimmunology: conditioning and stress. *Ann Rev Psychol.* 1993; 44: 53-85.
- [2] Moscoso M. From the mind to the cell: the impact of stress on psiconeuroimmunoendocrinology. *Liberabit.* 2009; 15(2): 143-152.
- [3] Ader R, Cohen N. Behaviorally conditioned immunosuppression. *Psychosom Med.* 1975; 37: 333-40.
- [4] Pondeljak N, Lugovi L. Stress-induced Interaction of Skin Immune Cells, Hormones, and Neurotransmitters. *Clinical Therapeutics.* 2020; 42(5): 757-770.
- [5] Shenefelt P. Psychological interventions in the management of common skin conditions. *Psychology Research and Behavior Management.* 2010; 3: 51–63.
- [6] Casariego Z. Síndrome de boca ardiente. *Avances en odontoestomatología.* 2009; 25(4): 194-202.
- [7] Camani E, Prado M, Vargas H, Motuca M, Páez S. Bruxismo: revisión sobre el papel del estrés psicosocial y la ansiedad en la génesis del fenómeno. *Facultad de Odontología. UNCuyo.* 2015; 9(2): 16-20.
- [8] Ruiz LS. Estrés y su relación etiopatogénica en la estomatitis aftosa recidivante. *Universidad Autónoma de Madrid, Facultad de Medicina, Valencia.* 2010.

- [9] Gómez de Ferraris ME, Campos Muñoz A. Capítulo 5-Cavidad bucal. "En Histología y embriología bucodental. Argentina, Editorial Panamericana, 2009; 122.
- [10] Pons Llorenc. Papel fisiológico de los neuropéptidos cutáneos: Presencia y actividades de SP y CGRP. *Offarm.* 2007; 26(6): 122-125.
- [11] Martin EI, Kerry J, Carpeta E, and Nemeroff CB. The Neurobiology of Anxiety Disorders: Brain Imaging, Genetics, and Psychoneuroendocrinology. *Psychiatr Clin North Am.* 2009; 32: 549-575.
- [12] Sánchez P, Sánchez J, de Lamo M, Peiró G. Psicobioquímica (estrés, ansiedad y depresión) en fibromialgia. *CM de Psicobioquímica.* 2014; 3: 55 - 68.
- [13] Marshall Baburizza M, Feldstedt González M, Fernández Moraga J, Fernández Moraga A, Esguep Sarah A. Prevalencia de Lengua Geográfica en Niños Chilenos de 7 a 10 Años de Edad. *Int. J. Odontostomat.* 2014; 8(2): 235-240.
- [14] Pascucci J, Albera E, Giaquinta M. Correlación entre estrés, tabaquismo y estado periodontal en adultos residentes en la ciudad de Mendoza. *Avances en Periodoncia.* 2016; 28(1): 11-22.
- [15] Maldonado J, Fuenmayor D, Taylor S. Métodos imagenológicos para la visualización de la articulación temporomandibular - Revisión de literatura. *Acta odontológica venezolana.* 2013; 51(1): 1-10.
- [16] Avaro R, De Elías R, Kiener O, Barzón S. Evaluación de inmunoglobulina e específica para distintos alérgenos y correlación con inmunoglobulina e total en pacientes con sospecha de enfermedades alérgicas. *Bioinforma digital.* 2019.
- [17] Truelove E, Sommers E, Leresche L, Dworkin S, Von Korff M. Clinical diagnostic criteria for TMD. New classification permits multiple diagnoses. *J Am Dent Assoc.* 1992; 123: 47-54.
- [18] Tafet G, Feder D. Efecto de la Psicoterapia Cognitiva en la regulación del Sistema Cortico- Límbico-Hipotálamo-Hipófiso-Adrenal en pacientes con Estrés Crónico. *Acta Psiquiátrica y Psicológica de América Latina.* 2005; 53(3): 163-168.
- [19] Bascones M, Valero A, Encinas A, Carrillo de Albornoz A, and Bascones A. Lengua geográfica y dermatitis atópica: una asociación frecuente. *Av Odontostomatol.* 2006; 22(2): 111-118.
- [20] Zumiga M, Farias X. Manía en niños y adolescentes. *Revista chilena Neuro-psiquiátrica.* 2002; 40(1): 31-40.
- [21] Alvarez S, Feijoo V. Características clínicas y epidemiológicas en pacientes con trastorno bipolar con ciclación rápida y sin ciclación rápida. *Revista Argentina de Clínica Neuropsiquiátrica.* 2005; 12(4): 371-382.
- [22] Mc Creary C, Clak G, Merrill R, Flack V, Oakley M. Psychological Distress and Diagnostic Subgroups of Temporomandibular Disorder Patients. *Pain.* 1991; 44: 29-34.
- [23] Simonić-Kocijan S, Uhač I, Braut V, Kovač Z, Kovačević Pavičić D, Fugošić V, et al. Influence of Chronic Stress and Oclusal Interference on Masseter Muscle Pain in Rat. *Collegium antropologicum.* 2009; 33(3): 863-866.
- [24] Durham J. Temporomandibular disorders (TMD): an overview. *Oral Surgery.* 2008; 1(2): 60-8.
- [25] Araya C, Oliva P, Ananías N, De los Santos P, Mendoza M. Temporomandibular and Anxiety Disorders in Workers of a Family Health Center in the Area of Concepción, Chile. *Int. J. Odontostomat.* 2011; 5(3).
- [26] Araneda P, Oyarzo J, Gonzáles M, Figueroa C. Intervención psicológica en trastornos temporomandibulares: Revisión narrativa. *J Oral Res.* 2013; 2(2): 86-90.
- [27] Rollman G, Gillespie J. The role of psychosocial factors in temporomandibular disorders. *Curr Rev Pain.* 2000; 4: 71-81.
- [28] Thomas J, Greene S, Dicken Ch. Factitious cheilitis. *J AM Acad Dermatol.* 1983; 8: 368-372.
- [29] Brocq L. *Prrcis-atlasde pratique dermatologique.* Paris 1921, GastonDoin & Cie, 854.
- [30] Tyldesley W. Exfoliative cheilitis. *Br. J. Oral Surg.* 1973; 10: 357-359.
- [31] Brooke RI. Exfoliative cheilitis. *Oral Surg.* 1978; 45: 52-55.
- [32] Woodburne A, Philpott O. Cheilitis glandularis: A manifestation of emotional disturbance. *Arc Dhermatol Syphilol.* 1950; 62: 820-827.
- [33] Reyes O, Jiménez N, Bello C. La lengua y sus múltiples patologías. Artículo de revisión. *C. D Med Oral.* 2009; 11 (3): 101-105.

- [34] Redman R, Vance F, Gorlin R, Peagler F, Meskin L. Psychological component in the Etiology of geographic tongue. *J Dent Res.* 1996; 45 (5): 1403-8.
- [35] Costa S, Hirota S, Takahashi M, Andrade H, Migliari D. Oral lesions in 166 patients with cutaneous psoriasis: a controlled study. *Med. Oral Patol. Oral Cir. Bucal.* 2009; 14(8): e371-5.
- [36] Goregen M, Melikoglu M, Miloglu O, Erdem T. Predisposition of allergy in patients with benign migratory glossitis. *Oral Surg. Oral Med. Oral Pathol. Oral Radiol. Endod.* 2010; 110(4): 470-4.
- [37] Ching V, Grushka M, Darling M, Su N. Increased prevalence of geographic tongue in burning mouth complaints: a retrospective study. *Oral Surg. Oral Med. Oral Pathol. Oral Radiol.* 2012; 114(4): 444-8.
- [38] González L, García M, Garcia J. Lengua geográfica: factores predisponentes, diagnóstico y tratamiento. Revisión sistemática. *Rev Clin Esp.* 2018; 218(9): 481-8.
- [39] Rezaei F, Fatholahi S, Rezaei F. Assessment of salivary antioxidant status and immunoglobulin E in patients with geographic tongue. *J Family Med Prim Care.* 2020; 9: 72-6.
- [40] Gómez B, Escobar A. Estrés y Sistema Inmune. *Rev Mex de Neuroci.* 2006; 7(1): 30-38.
- [41] Soria V, Uribe J, Salvat-Pujol N, Palao D, Menchón J, Labad J. Psiconeuroinmunología de los trastornos mentales. *Rev Psiquiatr Salud Ment (Barc.).* 2018; 11(2): 115-124.
- [42] Koczy-Baron E, Jochem J, Kasperska-Zajac A. Increased plasma concentration of vascular endothelial growth factor in patients with atopic dermatitis and its relation to disease severity and platelet activation. *Inflamm Res.* 2012; 61(12): 1405-1409.
- [43] Miranda C, Muiño J, Acosta C, and Dozo G. Relación entre el factor de crecimiento endotelial tipo a (vegf a) e ige sérica total en pacientes adultos con dermatitis atópica. *Archivos de Alergia e Inmunología Clínica.* 2019; 50(3): 114-120.
- [44] Ortiz M, Willey J, Chiang J. How stress gets under the skin o cómo el estrés psicológico se introduce bajo la piel. *Rev Med Chile.* 2014; 142: 767-774.
- [45] González S, Arias A, Elizondo B, Monge O. Psychoneuroimmunoendocrinology: clinical implications. *World Allergy Organ J.* 2017; 10(19).
- [46] Marchena L, Fernández C. Etiología de Lengua Geográfica. *Revista Europea de Odontoestomatología.* 2015; 14: 31-27.
- [47] Slominski A, Wortsman J, Tuckey R, Paus R. Differential expression of HPA axis homolog in the skin. *Mol Cell Endocrinol.* 2007; 265(266): 143-149.
- [48] Maarouf M, Maarouf C, Yosipovitch G, Shi V. The impact of stress on epidermal barrier function: an evidence-based review. *Br J Dermatol.* 2019; 181(6): 1129-1137.


---

## Author's short biography



### María Lourdes Rodríguez

Dentist specializing in Stomatology, Magister in Medical Molecular Biology, and PhD student from the School of Dentistry of the University of Buenos Aires. Professor of the Chair of Semiology and Stomatology Clinic, at the University of Cuenca-Ecuador.



### Zulema Juana Casariego

Specialist in Maxillofacial Surgery and Stomatology. Former Professor of Pathology and Stomatology and Pharmacology Clinic. Stomatologist of the Infectology Service by Hospital J A Fernández. Director of the Stomatology Specialty Clinic. Pontifical Catholic University Argentina. Fellow of International Dental Academy. Present National Academic Number.